



USE OF DUPLEX ULTRASOUND IN THE EVALUATION OF PATIENTS WITH CLINICAL SUSPICION OF DEEP VEIN THROMBOSIS ON THE LOWER EXTREMITIES

By

Waleed Tarek Sobhy, Khaled Lakouz MD ,Ahmed Abdelazem MD , and Rannia El-Mola MD.

Radio diagnosis Department, Faculty of Medicine, Zagazig University. Egypt

Received: 10 October 2018

Accepted: 28 December 2018

Corresponding author

Waleed Tarek Sobhy

Mahmoudwalead@yahoo.com

waleedtarek7799@yahoo.com.

ABSTRACT

Background : This study verify the role of duplex Doppler venous examination (DDVE) in assessment of possible alternative diagnoses when DVT of lower extremity is excluded in patient with painful swollen lower limb which is a common clinical presentation with DVT ; However ,not frequently a range of pathologies are instead diagnosed.

Objective : The aim of this work is to study the alternative diagnoses identified during duplex Doppler venous examinations (DDVE) of the lower extremities and their significance in patient management. The painful swollen lower limb is a common clinical presentation, with deep vein thrombosis (DVT) often the top differential.

Methods : This study was carried out at Radio diagnosis Department, Zagazig University Hospitals, The present study was carried on 42 patient with a painful swollen lower limb or lower limb edema. Diagnostic work up was done including ultrasound and duplex Doppler US.

Results : A total of 392 lower extremity venous Doppler examinations were reviewed and evaluated in 362 patients. Deep venous thrombosis was observed in 114 patients .Among the remaining 254 patients with unconfirmed DVT, 96 positive alternative diagnoses in 96 patients [representing 37.8% of patients negative for DVT (96/254) and 26.5% of all studied patients (96/362)] were identified.

Conclusion: The clinical diagnosis of DVT is challenging. Unilateral complaints such as painful swelling of the leg, with or without accompanying redness, are common symptoms of many conditions besides DVT. Duplex ultrasonography of the lower extremity has become the first-line diagnostic test to detect DVT, with a sensitivity of 91% to 96% and a specificity of 98% to 100 and also to assess other alternative diagnosis.

Keywords

- Deep Vein Thrombosis
- Venous Duplex Ultrasound Examinations
- Alternative diagnosis

INTRODUCTION

Deep venous thrombosis (DVT) is a major health problem and is estimated to have an incidence of 600,000 cases per year (1). Clinical signs and symptoms of

DVT are unreliable. If clinical signs alone were used to diagnose DVT, 42% of patients would receive unnecessary anticoagulation therapy. Most patients evaluated with ultrasonography (US) do not have DVT. The

key to making a precise diagnosis is recognizing the characteristics of various diseases on US images (2).

Studies conducted over the past 30 years have found that in 60%–80% of symptomatic patients, a diagnostic test can rule out DVT (Kahn, 1998). This means that approximately seven of 10 patients could have a cause other than DVT for pain, edema, mass, or erythema in the legs (3).

The most common causes of unilateral leg swelling are deep vein thrombosis (DVT), Baker's cyst, and cellulitis. Especially, it is important for physicians to make a diagnosis of DVT because of the life-threatening risk of pulmonary embolism as a consequence of DVT. Imaging modalities such as ultrasonography, contrast computed tomography (CT), magnetic resonance venography and venography are used to confirm the diagnosis of DVT (4).

Duplex ultrasonography of the lower extremity has become the first-line diagnostic test to detect DVT, with a sensitivity of 91% to 96% and a specificity of 98% to 100% (5).

Alternative diagnoses, which occur frequently and are significant, should be considered when performing a duplex Doppler venous examinations (DDVE), because ultrasonography is the only commonly used imaging modality by which these alternative diagnoses can be made (6). Of the other modalities commonly used in the diagnosis of DVT (i.e., contrast venography, impedance plethysmography, or nuclear medicine fibrinogen studies), none is capable of rendering an alternative positive diagnosis. Magnetic resonance imaging can evaluate for DVT and theoretically could identify alternative diagnoses, but this imaging modality is not commonly used (7).

The differential diagnoses of deep vein thrombosis affecting the lower extremities include infectious, neoplastic, traumatic, inflammatory, vascular, and miscellaneous entities (2).

MATERIALS & METHODS

I-Patients

During the period from September 2017 to May 2018, 362 consecutive patients

from Emergency department and Inpatient services of the Zagazig University Hospitals with suspected deep venous thrombosis of the lower extremity; on the basis of clinical symptoms and results of laboratory findings; were enrolled in this study. They were sent to Radiology Department for lower limb venous Doppler ultrasound. They were 191 males and 171 females. The age of patients ranged from 20 to 78 years with a mean age of 45 years.

The 362 patients underwent comprehensive lower limb venous Doppler ultrasound. A question of bilateral lower-extremity DVT was raised in 30 patients, necessitating bilateral evaluation; therefore, a total of 392 lower extremities were evaluated.

Inclusion criteria:

1-All patients presenting with the clinical diagnosis of deep vein thrombosis.

2-Patients with long term immobilization or other risk factors for deep vein thrombosis.

Exclusion Criteria :

-All the patients who are not willing to be a part of the study.

II- Methods

All patients were subjected to the following-:

1-Full history taking:

- a. Onset, course and duration of the present illness.
- b. Personal history: including the age, sex, occupation, residency and special habits as smoking .
- c. Relevant risk factors for lower extremity peripheral venous disease: previous deep vein and/or superficial vein thrombosis (DVT/SVT), lower extremity trauma, immobilization of extremity, recent major surgery, prolonged bed rest, history of cancer, family history of DVT or pulmonary embolism, pregnancy, congestive heart failure (CHF) or other similar cardiac problems .
- d. Presence of comorbidity: diabetes mellitus, chronic obstructive pulmonary disease, hypertension, heart disease, obesity, etc .
- e. Current medications or therapies.

f. Results of other relevant diagnostic procedures.

II-Clinical examination:

General examination and focused physical examination of the affected lower extremity which includes observation and localization of the presence of any signs or symptoms of peripheral venous disease: swelling, pain, tenderness, palpable cord, discoloration, varicosities, ulceration and shortness of breath .

III-Laboratory investigations:

- Including hemoglobin level, leukocytes, and platelets counts, INR, quantitative D-dimer level, and activated partial thromboplastin time

IV-Venous duplex ultrasound examination of lower limb:

A comprehensive lower extremity venous duplex US examination for the evaluation of DVT was performed in the Department of Radio-diagnosis, Zagazig University Hospitals. The equipments used were Siemens Acuson X300 USG machine (Probe frequency range-Linear: 10-5 MHz, Curvilinear: 6-2 MHz) and General Electric, Logiq P5 (Probe frequency range-Linear: 13-7 MHz, Curvilinear: 5-2 MHz). Linear array transducers were used for femoral and popliteal venous segments and for calf veins. Convex transducers were used for evaluation of iliac veins and IVC.

In addition to assessment of the lower extremity veins for DVT, an extended sonographic evaluation of the symptomatic area in the lower extremity was done to identify non-thrombotic abnormalities that may require immediate intervention or close follow up. This portion of the examination proved to be important in identifying the cause for the patient's symptoms when no DVT could be found.

Technique of venous duplex ultrasound examination of lower limb:

To ensure adequate distention of the venous system, the patients were examined in a sitting position or in reverse Trendelenburg's position at about 15 or 20°, with the leg in slight external rotation .

The examination began at the groin, where the common femoral vein was located on a

transverse scan. Assessment included the common femoral, deep femoral and the superficial femoral veins to the level of the adductor hiatus. An effort was made to image the superficial femoral vein within the Hunter canal and as it exited the adductor hiatus.

The saphenous vein was also visualized, and the point of union of the saphenous vein with the common femoral vein was always observed. Position and appearance of the femoral artery were also noted, as well as any masses or fluid collections in the perivascular area.

The scan plane was then changed to longitudinal and the vein examined with color Doppler, or power Doppler, as the transducer was moved up the thigh. Squeezing the calf gently will augment flow and allow easier detection of areas of flow or thrombosis; alternatively, the patients can be asked to plantar-flex their toes, which results in calf muscle contraction and emptying of the calf veins.

After direct visualization of the veins, in both transverse and longitudinal projections, compression (at intervals of 2–3 cm) was applied. At the adductor canal, the superficial femoral vein was difficult to compress from an anterior approach as it is well supported by the bulk of the anterior thigh muscles. Compression was better achieved in this region by placing a hand behind the medial thigh and pushing up with the fingers against the transducer.

The following criteria were described by **Goran ,et,al** for DVT diagnosis:

- 1 .Visualization of thrombus.
- 2 .Vein compressibility.
- 3 .Vein size.
- 4 .Respiratory changes.

The veins were evaluated for:

- 1 .Absent or reduced compressibility of the vein.
- 2 .Thrombus in the vein, static echoes in complete color fill in full expansion of vein.
- 3 .Static valve leaflets.
- 4 .Absent flow on spectral color Doppler.
- 5 .Impaired or absent augmentation of flow.
- 6 . Loss of spontaneous and respiratory variation.

STATISTICAL ANALYSIS

The findings of venous duplex ultrasound examination of lower limb and extended sonographic evaluation of the symptomatic area were evaluated and correlated to the final diagnosis. Results were expressed as percentages.

RESULTS

A total of 392 lower extremity venous Doppler examinations were reviewed and evaluated in 362 patients. They were 191 males and 171 females [Table 1]. Their ages ranged from 20 to 78 years with a mean age of 45 years [Table 2]. The most common age group was 50-<60 years (89 patients, 24.6%).

Table 1 shows sex distribution of the patients in this study.

Sex	Number	Percentage
Male	191	53%
Female	171	47 %
Total	362	100%

Table 2: shows age distribution of the patients in this study.

Age (years)	Number	Percentage
20-<30	59	16.4 %
30-<40	76	20.9%
40-<50	71	19.6%
50-<60	89	24.6%
≥60	67	18.5%
Total	362	100%

Our patients had different clinical presentations [Table 3]. The most considerable clinical symptoms for performing lower limb venous Doppler ultrasound were limb swelling which was detected in 86 cases (23.8%) and pain and swelling detected in 74 patients (20.4%), calf or thigh pain/tenderness detected in 59 patients (16.3%), while 3.3% of patients presented with pulmonary embolism.

Table 3: shows clinical parameters for performing duplex scan.

Clinical parameter	Number	Percentage
Limb swelling	86	23.8%
Pain and swelling	74	20.4%
Calf or thigh pain/tenderness	59	16.3%
Joint pain	49	13.5%
Hyperthermia	34	9.4%
Erythema	18	5%
Cellulitis	14	3.9%
Cyanosis	16	4.4%
Pulmonary embolism	12	3.3%
Total	362	100%

Complete thrombosis was observed in 79/114 (69%), while partial thrombosis was observed in 35/114 (31%). Thus predominant type of occlusion was that of the complete type followed by partial type [Table 4].

Table 4: shows stage of involvement of the thrombus.

Stage of involvement	No. of cases	Percentage
Acute	71	62 %
Subacute	25	22 %
Chronic	18	16 %
Total	114	100 %

DISCUSSION

Found in both outpatients and inpatients and affecting over 20 million individuals annually in the United States, acute deep venous thrombosis (DVT) is of great clinical concern. Predisposing factors are venous stasis from inactivity or congestive heart failure, pelvic or lower extremity surgery, pregnancy, obesity, coagulopathy, paralysis, or malignancy. The prompt diagnosis of DVT is critical because of its association with acute pulmonary embolism, which occurs in up to 50% of cases of untreated DVT and carries a 30% mortality rate. However, the clinical accuracy of diagnosing DVT and its location is generally poor (8)

Approximately 90% of pulmonary emboli arise from the lower extremities (Needleman, et al., 1998). Thrombosis in the calf may cause symptoms in the thigh and vice versa. Patients with bilateral leg symptoms in the absence of significant risk factors should first be assessed for cardiac

disease or chronic peripheral vascular disease. If significant risk factors exist, ultrasound is warranted (9)

Duplex ultrasonography of the lower extremity has become the first-line diagnostic test to detect DVT, with a sensitivity of 91% to 96% and a specificity of 98% to 100% (10). In cases of isolated calf vein thrombosis, serial Doppler study (once weekly for 2 weeks) is suggested for propagation of thrombus into the proximal veins (popliteal vein or above) (11).

Only a small proportion (15–25%) of patients with clinically suspected DVT have objective evidence of thrombosis when evaluated by ultrasonography (12). As a result, an alternative diagnosis is considered in a majority of patients. Few prior studies have explored alternate diagnoses in patients with suspected DVT who received a lower extremity US examination (13)

In our study, 53% of the patients were males and 47% were females. Thus males slightly dominated the study group. This

correlates well with the study conducted by **De Oliveira** who reported that there was a higher incidence of DVT among males. The age group of patients ranged from 20 to 78 years in our study. The majority of the patients belonged to the 5th decade (24.6%). This was similar to study conducted by **Khaladkar et al. (2014)**, where the mean age of patients was in the 5th decade. In the study conducted by **Hill et al. (14)** they found that mean age of patients shown to have DVT was in 6th decade.

The majority of the patients in our study had edema as the most common presenting symptom which constituted (23.8%) of all patients, followed by pain and edema (20.4%) and pain/tenderness (16.3%). This correlates well with the study conducted by **Glover and Bendick (1996)** and **Eze et al. (1996) (15)** who reported that only 5% of patients were found to have DVT in absence of leg swelling. This is well explained by the normal venous physiology that when major venous channels get occluded, there is resultant increase in venous pressure and volume which manifests into edema. This also correlates with the study conducted by **Langsfeld et al. (1987)** who found edema as the most common sign in patients diagnosed with DVT(16).

In our study the most common predisposing condition for DVT was recent surgery/postoperative status (66 cases, 18%), followed by prolonged bed rest (58 cases, 16%), immobilization of extremity (38 cases, 10.5%), pregnancy/postpartum status (32 cases, 8.8%), and hospitalization (28 cases, 8%). However no predisposing condition was found in 6.6% of the patients. Heit et al. (2000) concluded in their study that hospital or nursing home confinement, surgery, trauma, malignant neoplasm, chemotherapy are independent and important risk factors for venous thromboembolism.

Using the criteria for diagnosis of DVT, 108/362 (29.8%) patients were positive for DVT and 254/362 (70.2%) patients were negative for DVT. Bilateral lower limb DVT was observed in 6 /108cases (5.5%), unilateral lower limb involvement was seen in 102/108 cases (94.5%), thus showing

predominant unilateral lower limb involvement. The total number of extremities involved was 114.

The full differential diagnosis should be considered in possible cases of DVT including Baker's cyst, cellulitis, lymphedema, chronic venous insufficiency, superficial thrombophlebitis, popliteal venous or arterial aneurysm, enlarged lymph nodes compressing the veins, heterotopic ossification, hematoma, and muscle tears. Duplex Doppler compression ultrasound is the current study of choice for the diagnosis of suspected DVT (17).

The positive alternative diagnoses were classified into vascular (33.3%, 32/96) and nonvascular (66.7%, 64/96) alternative diagnoses. Nonvascular alternative diagnoses were more common than vascular alternative diagnoses. Alternative vascular diagnoses necessitated more immediate therapy.

The vascular alternative diagnoses (33.3%, 32/96) could be summarized in arterial and venous causes including aneurysm (3cases), pseudoaneurysm (4 cases), arterial occlusion (3cases), superficial venous system thrombosis (5 cases), ilioacaval thrombosis (4 cases), and chronic venous insufficiency (13 cases).

In our series, the three aneurysms (one affecting superficial femoral artery and 2 affecting popliteal artery), and four pseudoaneurysms (2affecting the superficial femoral artery, one affecting anterior tibial artery and one involving peroneal artery) compressing their related veins were identified and repaired surgically .

Among the nonvascular alternative diagnoses, cellulitis (19.4%) was the most frequent, followed by Baker's cyst (16.6%), muscle tear/hematoma (11.1%), soft-tissue neoplasms(9.7%), lymphadenopathy(5,6.9%), pyomyositis/abscess (6.9%), tendon pathology (6.9%), arthritis (4.2%) and miscellaneous (13, 18%) .

CONCLUSION

The clinical diagnosis of deep venous thrombosis (DVT) is challenging. Unilateral complaints such as painful swelling of the leg, with or without accompanying redness, are common symptoms of many conditions

besides DVT. Imaging modalities such as ultrasonography, contrast computed tomography (CT), magnetic resonance venography and conventional venography are used to confirm the diagnosis of DVT.

In addition to assessment of the lower extremity veins for DVT, an extended sonographic evaluation of the symptomatic area in the lower extremity was done to identify non-thrombotic abnormalities that may require immediate intervention or close follow up. This portion of the examination proved to be important in identifying the cause for the patient's symptoms when no DVT could be found.

The most considerable clinical symptoms for performing lower limb venous Doppler ultrasound were limb swelling which was detected in 86 cases (23.8%) and pain and swelling in 74 patients (20.4%), calf or thigh pain/tenderness in 59 patients (16.3%), while 3.3% of patients presented with pulmonary embolism.

The risk factors for DVT were recent surgery/postoperative status (detected in 18% of cases), prolonged bed rest (16%), immobilization of extremity (10.5%), Pregnancy/postpartum status (8.8%), and hospitalization (7.7%). However no predisposing condition was found in 8.8% of the patients.

Using the criteria described earlier, for diagnosis of DVT, 108/362 (29.8%) patients were positive for DVT and 254/362 (70.2%) patients were negative for DVT. Bilateral lower limb DVT was observed in 6/108 cases (5.5%), unilateral lower limb involvement was seen in 102/108 cases (94.5%), thus showing predominant unilateral lower limb involvement. The total number of extremities involved was 114.

Predominant distribution of thrombosis in our study was found to be in the popliteal and infrapopliteal region with 80% (n=95) of the patients having thrombus in the popliteal vein, followed by thrombus in posterior tibial vein, 73% (n=87). Superficial femoral vein was involved in 62% of the patients (n=74), as compared to the isolated calf DVT which was detected in 7% (n=8).

The predominant stage of DVT was that of acute thrombus (62%), followed by subacute stage (22%) and chronic stage (16%).

Among the remaining 254 patients with unconfirmed DVT, 96 positive alternative diagnoses in 96 patients [representing 37.8% of patients negative for DVT (96/254) and 26.5% of all studied patients (96/362)] were identified. These positive alternative diagnoses were believed to account for patient's symptoms and changed the clinical management.

The positive alternative diagnoses were classified into vascular (33.3%, 32/96) and nonvascular (66.7%, 64/96) alternative diagnoses.

The vascular alternative diagnoses (33.3%, 32/96) could be summarized in arterial and venous causes including aneurysm (3 cases), pseudoaneurysm (4 cases) (**Fig 1**), arterial occlusion (3 cases), superficial venous system thrombosis (5 cases), ilio caval thrombosis (4 cases), and chronic venous insufficiency (13 cases).

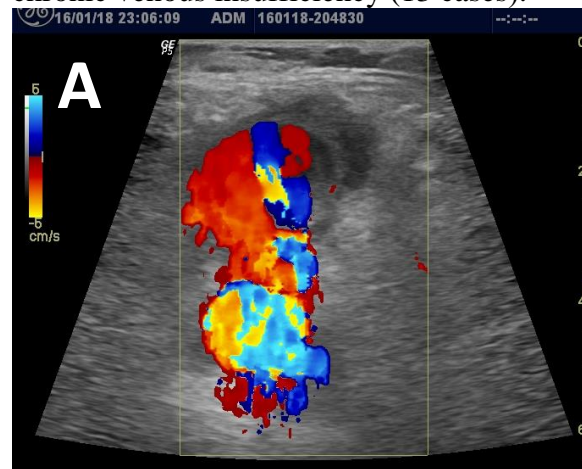
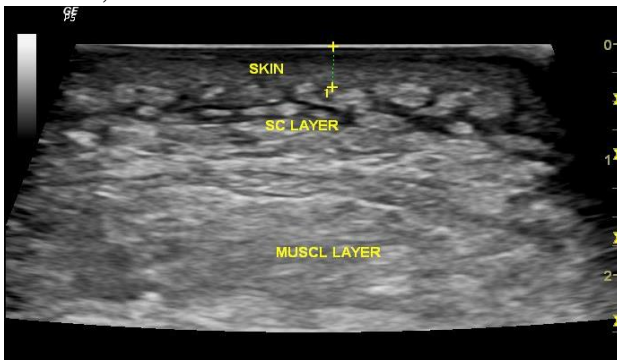


Fig 1. A case of pseudoaneurysm of right superficial femoral artery. Color flow Doppler images demonstrate a large pseudoaneurysm measuring 5.5x3.5 cm in diameters arising from superficial femoral artery. The pseudoaneurysm shows the typical swirling motions and to- and fro- movements.

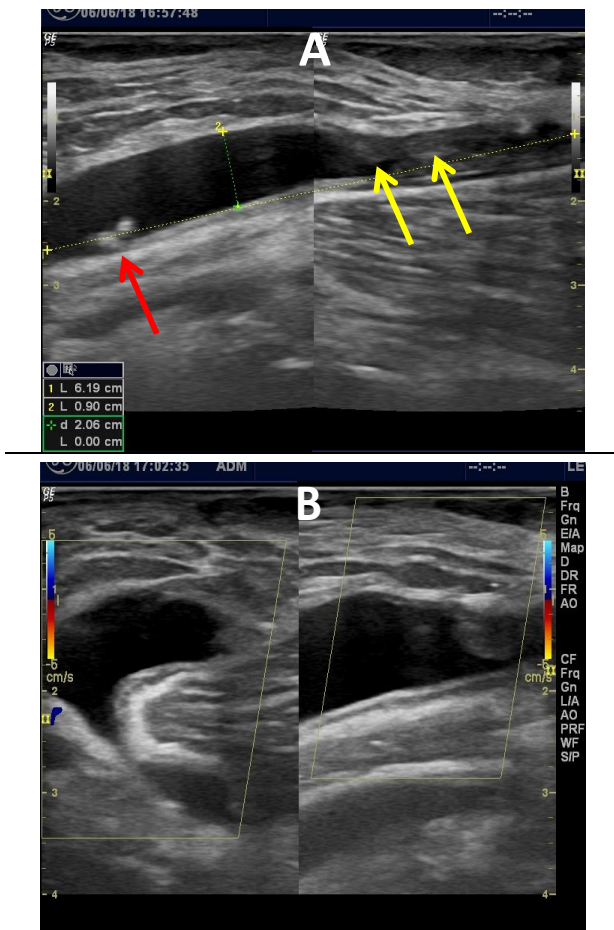
Among nonvascular alternative diagnoses, cellulitis (n=14, 14.6%) was the most frequent (**Fig 2 a.b**), followed by Baker's cyst (n=12, 12.5%) (**Fig 3 a.b**), muscle tear/hematoma (n=7, 7.3%), soft-tissue neoplasms (n=6, 6.3%), lymphadenopathy

(n=5, 5.2%), pyomyositis/abscess (n=5, 5.2%), Tendon pathology (n=4, 4.2%), arthritis (n=3, 3.1%) and miscellaneous (n=8, 8.4%).

;lsdssf



(A)US image of the leg demonstrates thickening of skin and subcutaneous tissue with increased echogenicity and accumulation of fluid in the subcutaneous tissue giving it a “cobble stone appearance”.



(Fig. 3)A case of ruptured Baker's cyst .(A) Long axis US image of popliteal fossa shows oblong-shaped cyst with calcific bodies (red arrows) and echogenic content (yellow arrows) within.

(B).Color flow Doppler imaging of popliteal fossa reveals no internal vasculature of the cyst.

Alternative diagnoses occur frequently and are significant in patient management. These alternative diagnoses should be considered when a DDVE is performed, because ultrasonography is the only commonly used imaging modality of the venous system by which they can be made.

Alternative diagnoses occur frequently and are significant in patient management. These alternative diagnoses should be considered when a DDVE is performed, because ultrasonography is the only commonly used imaging modality of the venous system by which they can be made.

REFERENCES

1. DiVittorio, R., Bluth, E. I., & Sullivan, M. A. (2002). Deep vein thrombosis: diagnosis of a comon clinical problem. *The Ochsner Journal*, 4(1), 14-17.
2. Adhikari, S., & Zeger, W. (2015). Non-thrombotic abnormalities on lower extremity venous duplex ultrasound examinations. *Western Journal of Emergency Medicine*, 16(2), 250.
3. Ten Cate-Hoek, A. J., van der Velde, E. F., Toll, D. B., van Weert, H. C. P. M., Moons, K. G. M., Büller, H. R., ... & Stoffers, H. E. J. H. (2012). Common alternative diagnoses in general practice when deep venous thrombosis is excluded. *Neth J Med*, 70(3), 130-5.
4. Hamper, U. M., DeJong, M. R., & Scutt, L. M. (2007). Ultrasound evaluation of the lower extremity veins. *Radiologic Clinics*, 45(3), 525-547.
5. Bhanusupriya Somarouthu MBBS, Suhny Abbara MD & Sanjeeva P. Kalva MD (2010) Diagnosing Deep Vein Thrombosis, *Postgraduate Medicine*, 122:2, 66-73
6. Borgstede, J. P., & Clagett, G. E. (1992). Types, frequency, and significance of alternative diagnoses found during duplex Doppler venous examinations of the lower extremities. *Journal of ultrasound in medicine*, 11(3), 85-89.
7. Hansson, P. O., Sörbo, J., & Eriksson, H. (2000). Recurrent venous thromboembolism after deep vein thrombosis: incidence and risk factors. *Archives of internal medicine*, 160(6), 769-774.

8. Cronan, J. J., Dorfman, G. S., & Grusmark, J. (1988). Lower-extremity deep venous thrombosis: further experience with and refinements of US assessment. *Radiology*, 168(1), 101-107.
9. Heit, J. A., Silverstein, M. D., Mohr, D. N., Petterson, T. M., O'fallon, W. M., & Melton, L. J. (2000). Risk factors for deep vein thrombosis and pulmonary embolism: a population-based case-control study. *Archives of internal medicine*, 160(6), 809-815.
10. Magazzini, S., Vanni, S., Toccafondi, S., Paladini, B., Zanobetti, M., Giannazzo, G., ... & Grifoni, S. (2007). Duplex ultrasound in the emergency department for the diagnostic management of clinically suspected deep vein thrombosis. *Academic Emergency Medicine*, 14(3), 216-220.
11. Ozaki, A., & Bartholomew, J. R. (2012). *Pulmonary Embolism*. Cleveland Clinic. Cleveland. Clinic.
12. Sutter, M. E., Turnipseed, S. D., Diercks, D. B., Samuel, P., & White, R. H. (2009). Venous ultrasound testing for suspected thrombosis: incidence of significant non-thrombotic findings. *Journal of Emergency Medicine*, 36(1), 55-59.
13. De Oliveira, A., França, G. J., Vidal, E. A., Stalke, P. S., & Baroncini, L. A. (2008). Duplex scan in patients with clinical suspicion of deep venous thrombosis. *Cardiovascular Ultrasound*, 6(1), 53.
14. Hill, S. L., Holtzman, G. I., Martin, D., Evans, P., Toler, W., & Goad, K. (1997). The origin of lower extremity deep vein thrombi in acute venous thrombosis. *The American journal of surgery*, 173(6), 485-490.
15. Glover, J. L., & Bendick, P. J. (1996). Appropriate indications for venous duplex ultrasonographic examinations. *Surgery*, 120(4), 725-731.
16. Langsfeld, M., Hershey, F. B., Thorpe, L., Auer, A. I., Binnington, H. B., Hurley, J. J., & Woods, J. J. (1987). Duplex B-mode imaging for the diagnosis of deep venous thrombosis. *Arch Surg*, 122(5), 587-591.
17. Bluth, E. I. (2000). Leg swelling with pain or edema. *Ultrasound: A Practical Approach to Clinical Problems*. New York: Thieme, 534-545.

How to cite this article: Sobhy WT, Lakouz K, Abdelazem A, El-Mola R. Use of duplex ultrasound in the evaluation of patients with clinical suspicion of deep venous thrombosis on the lower extremities. *ZUMJ* 2019; 25 (1): 55-63.