

## ANALGESIC EFFICACY OF ULTRA-SOUND GUIDED TRANSVERSUS ABDOMINIS PLANE (TAP) BLOCK WITH TOTAL ABDOMINAL HYSTERECTOMY

*Ismail Mohammed Abd El Gawad , Ayman Salah Emara , Said Mostafa Abd El Hameed,  
Mohammed El Shahat Elsayed*

*Anesthesia Department Al Azhar University, Cairo Egypt*

### ABSTRACT

**Background:** Pre-incisional bilateral Ultra-sound guided transverses abdominis plane (TAP) block is a novel approach for blocking the abdominal wall neural afferents for postoperative analgesia. The aim of this study is, assess the effectiveness of Ultra-sound guided TAP block on requirement of intra-operative fentanyl and post-operative analgesia in patients undergoing total abdominal hysterectomy. **Subjects and Methods:** Eighty patients ASA physical status I and II, were randomly allocated into two groups (40 patients each), **group TAP:** received bilateral Ultra-sound guided TAP block with 20ml bupivacaine 0.25% in each side and **group GA:** received Ultra-sound guided TAP with same volume of normal saline. both groups given standardized GA. Intra-operative fentanyl requirements and postoperative pain using visual analogue score (VAS) at 30 min.1, 2, 3, 6, 12 and 24 h post-operatively were assessed and if VAS  $\geq 3$ , patients received i.v. pethidine as a rescue analgesic and time to first request of analgesia was recorded. **Results:** Intra-operative fentanyl requirement reduced in TAP group compared to GA group; it was  $100.4 \pm 21.6$  and  $150.3 \pm 24.3$  mcg respectively. Time to the first analgesic request was also reduced in TAP group compared to GA group; it was  $112.5 \pm 5.4$  min. vs.  $23.4 \pm 2.3$  min respectively. VAS at most post-operative measurement points and pethidine requirement were reduced in TAP group compared to GA group; (41.7 and 92.3 mg respectively). There were no recorded complications attributed to the TAP block procedure. All TAP group patients were highly satisfied with their postoperative analgesic regimen. **Conclusion:** TAP block provides effective intra and postoperative analgesia, prolongs time to the first analgesic request and reduces total intra and postoperative analgesic consumption with minimal PONV after total abdominal hysterectomy. **Keywords:** perioperative analgesia, ultrasound guided transversus abdominis plane block.

**Corresponding author:** Ayman Salah Emara-

**Tel:** 00201100296896

**Email:** Aymanbeng@yahoo.com

**Received:** 13 September 2015

**Accepted:** 30 September 2015

### INTRODUCTION

Postoperative analgesia regimen decreases the stress response to surgery, help in early recovery and ambulation which leads to a better outcome after abdominal surgery.<sup>[1-2]</sup> The most common drugs for postoperative analgesia are non-steroidal anti-inflammatory drugs (NSAIDs) and opioids but there are severe side effects of these drugs such as nausea, vomiting, respiratory depression and sedation. Therefore, the use of non-opioid analgesic techniques such as regional and abdominal wall field blocks can lead to good quality of recovery for surgical patients.<sup>[3]</sup>

Transversus abdominis plane (TAP) block, a popular analgesic technique since first described by Rafiin in 2001 as a landmark-based technique where the needle puncture is performed subcutaneously with a series of 'fascial clicks' within the ilio-lumbar triangle of Petit.<sup>[4-5]</sup> This triangle is bounded posteriorly by the latissimus dorsi muscle and anteriorly by the external oblique, with the iliac crest forming the base of the triangle, and is a fixed and easily palpable landmark.<sup>[6]</sup>

In TAP block the abdominal wall afferent neurons are blocked by injecting the local anesthetic into the plane between the internal oblique and transverses abdominis muscles, which contain anterior rami of the lower 6

thoracic nerves (T7 to T12) and the first lumbar nerve (L1) that innervate the anterior abdominal wall (skin, muscles, parietal peritoneum).<sup>[7]</sup>

The transversus abdominis plane (TAP) block, a field block, has subsequently been used for postoperative pain relief in several abdominal surgeries such as large bowel resection,<sup>[8]</sup> open appendectomy,<sup>[9]</sup> retropubic prostatectomy,<sup>[10]</sup> hernia repair,<sup>[11]</sup> and cesarean section.<sup>[12]</sup>

The blind technique was difficult and may carries potential risk of possible visceral injury,<sup>[13]</sup> so TAB block was done with ultra-sound guidance To minimize these complication.<sup>[14-15]</sup>

The aim of this study were to assess the effect of TAB block on intraoperative, postoperative opioid requirements and postoperative pain scores in the first 24 hours in patients undergoing total abdominal hysterectomy(TAH).

### SUBJECTS AND METHODS

This randomized, controlled, double-blind clinical study was conducted in *Bab El-sharia hospital, faculty of medicine, Al-Azhar University, Cairo, Egypt*, from September 2014 to July 2015. Patients having a history of allergy to any drug used in this study, body mass index >30 kg/m<sup>2</sup>, compromised renal and liver function, uncontrolled diabetes, severe cardiovascular, respiratory disease were excluded. After approval of ethics institutional committee and written informed consent, eighty patients ASA physical status I-III, aged between 45 and 64 years were scheduled for TAH by suprapubic abdominal transverse incision and Patients were randomized, by sealed envelopes to two groups (40 patients each). **Group TAP:** received general anesthesia with bilateral Ultra-sound guided TAP block with 20ml bupivacaine 0.25% in each side and **group GA:** received general anesthesia with Ultra-sound guided TAP with same volume of normal saline.

Electrocardiogram, arterial oxygen saturation, arterial blood pressure and End-tidal carbon

dioxide monitoring were attached to patients and after induction of standardized general anesthesia with i.v Fentanyl (1,5 µg/kg), Propofol (2 mg/kg) and Atracurium (0.5mg/kg). Endotracheal tube insertion was performed by an experienced anaesthesiologist after ensuring maximum neuromuscular blocking effect as assessed by train of four (TOF) count <2. Anesthesia was maintained with sevoflurane in a concentration of 2% with 100% oxygen and mechanical ventilation with an initial tidal volume of 8 mL/kg and respiratory frequency of 12 breaths min were used to maintain normocapnia. Group TAP received bilateral ultra-sound guided TAP block with 20 ml bupivacaine 0.25% in each side and group GA received ultra-sound guided TAP with the same volume of normal saline. The solution was prepared in identical syringes and patients, the anesthesiologists, and the staffs providing postoperative care were blinded to group assignment. Intraoperative fluid requirements must be calculated according to body weight of the patients and intraoperative blood loss must be replaced by fluid or blood transfusion if blood loss more than 20% of total blood volume of the patient to avoid hemodynamic changes with hypovolemia and to obtain accurate results of intraoperative hemodynamic changes with TAB block. At the end of the surgery, residual neuromuscular block was antagonized by a combination of neostigmine 0.05 mg/kg and glycopyrolate 0.01 mg/kg. Endotracheal tube was removed at T4/T1 ratio of > 90% and the patient fully conscious.

### Ultrasound guided TAP

After complete sterilization, linear ultrasound probe was placed transverse to the abdominal wall between the costal margin and iliac crest. The image produced shows (from above downwards) skin, subcutaneous tissue and fat, external oblique, internal oblique, transversus abdominis. The peritoneum and bowel loops may also be visualized deeper to the muscles. **(Figure 1)**

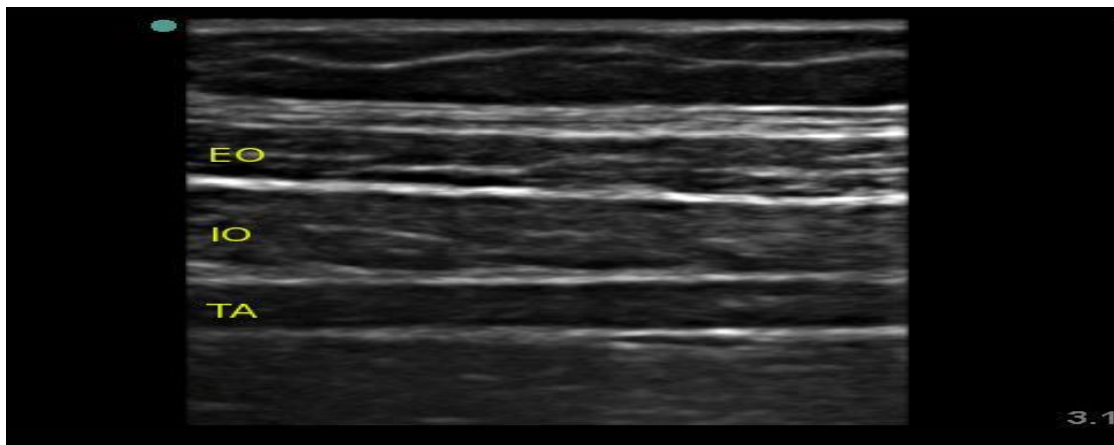


Figure (1): Sono-anatomy of the structures of the abdominal wall. EO= external oblique, IO= internal oblique, TA = transversus abdominis

The needle was introduced in plane and advanced until it reaches the plane between the internal oblique and transversus abdominis muscles. Upon reaching the plane, 2 ml of saline was injected to confirm correct needle position, after which 20 ml 0.25% bupivacaine was injected slowly. The transversus abdominis plane was visualized expanding with the injection (**Figure 2**) then same procedure was done on the other side. Following TAP block the surgical procedure was carried out in usual manner. Intra-operatively, if blood pressure

and/or heart rate were increased more than 20% of basal, 50 µg fentanyl was administered and recorded. Postoperative visual analogue score (VAS) for pain was recorded at 0, 30 min, 1, 2, 3, 6, 12 and 24 hrs and if VAS was  $\geq 3$ , pethidine 1 mg/kg was received i.v. and time to first analgesic request (min) and also total analgesic consumption were recorded. The incidence and severity of postoperative complications such as nausea and/or vomiting was recorded during the first 24 hour postoperative.

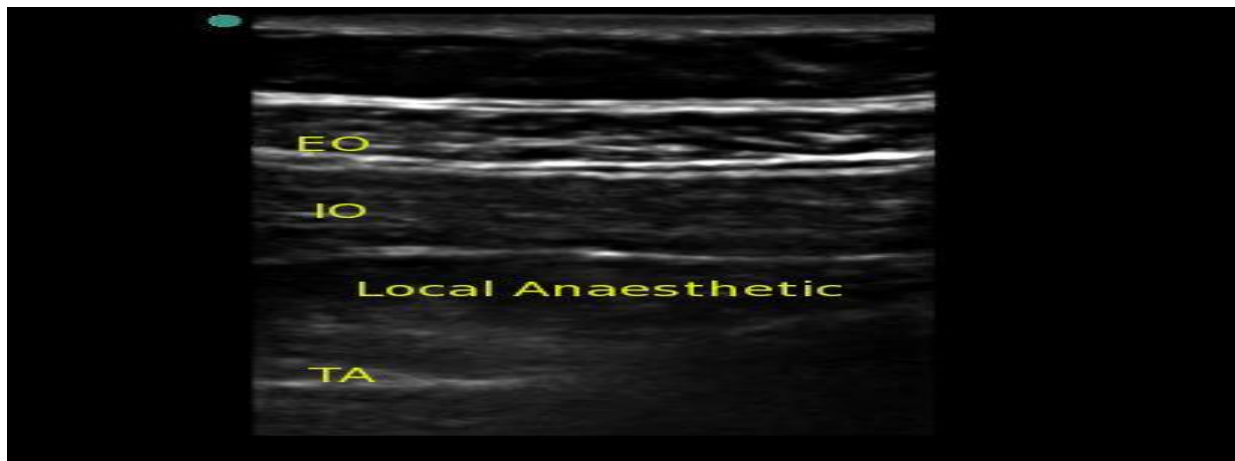


Figure (2): TAP Block after injection of local anesthetic into the transversus abdominis plane.

#### Statistical Analysis:

SPSS version 17 programs were used to enter data and statistical analysis. Data were presented as Mean  $\pm$  SD, range, and number. parametric data in both groups was

compared by unpaired Student's *t*-tests, and Mann-Whitney test for nonparametric ordinal data. For data collected as proportions Chi-squared test ( $\chi^2$ ) and Fisher exact test were performed *P*value  $< 0.05$  was considered significant.

## RESULTS

Patient characteristics, clinical data, the durations of surgery and anesthesia were comparable (Table 1).

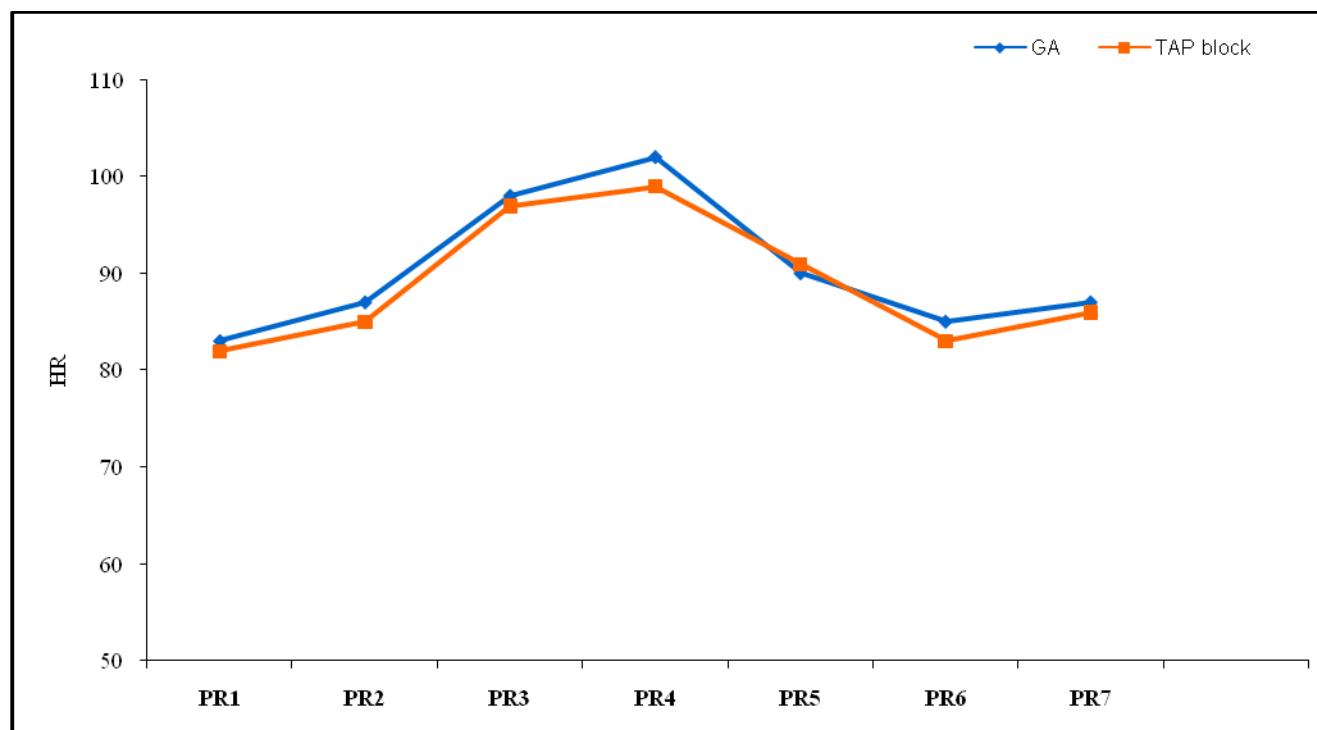
**Table (1): Patients characteristics, clinical data, the durations of surgery and anesthesia.**

Variable	GA (n=40)	TAP (n=40)	P-value
Age (yr)	61.3±8.4	60.9±7.6	0.823
Weight (kg)	66.4 ± 3.5	65.7 ± 3.3	0.360
Height (m)	1.63 ± 0.14	1.66 ± 0.21	0.454
ASA (I-II-III)	17/13/10	22/9/9	0.491
HR (min)	83.0±8.7	82.4±8.4	0.754
MABP(mmHg)	108±7.2	109±9.6	0.634
Duration of surgery (min)	62.6±5.6	60.3±4.9	0.054
Duration of anesthesia (min)	74.4±8	72.3±7.6	0.253
Incision size (cm)	7.3±1.8	7.9±1.5	0.109

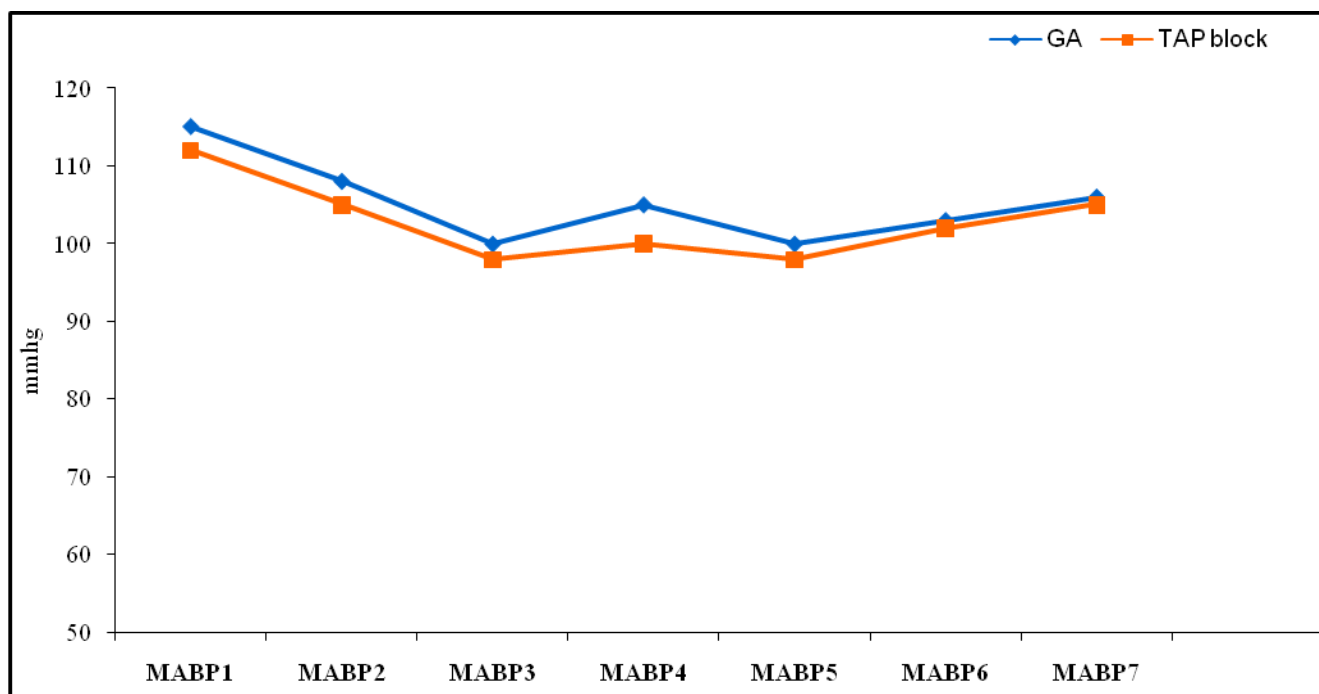
Data are expressed as mean ± SD or number

HR=heart rate- MABP=mean arterial blood pressure

Intra-operative heart rate and Mean arterial blood pressure were significantly higher in GA group compared to TAP group at all measurements intervals (**Figures 3, 4**)



**Figure 3.** Pulse rate, PR1 =before induction, PR2 =after induction, PR3 = 15 min after TAP block, PR4 = after incision, PR5 = 15 min intraoperative, PR6 =30 min intraoperative, PR7 = 60 min intraoperative.



**Figure (4):** Mean arterial blood pressure, MABP1 =before induction, MABP2 =after induction. MABP3 = 15 min after TAP block, MABP4 = after incision, MABP5 = 15 min intra-operative, MABP6 = 30 min intra-operative, MABP7 = 60 min intra-operative.

Intraoperative fentanyl requirement was significantly higher in GA group in comparison to TAP group and time to first analgesic request was significantly prolonged in TAP group compared to GA group. Incidence of

postoperative nausea-vomiting was none significantly but higher in GA group than TAP group (**Table 2**). No other complications reported with TAP block.

**Table (2):** Intraoperative fentanyl requirement, time to requirement of first analgesic (min), and PONV incidence.

Variable	GA	TAP
P value		
	(n=40)	(n = 40)
Intraoperative fentanyl Requirement(mcg)	150.3±24.3	100.4± 21.6
<0.001*		
Time to requirement of first analgesic (min)	23.4± 2.3	112.5±5.4
<0.001*		
PONV (yes/no)	9/31	3/37
0.117		

Data are expressed as mean ± SD or number. PONV= postoperative nausea-vomiting

\*= significant to other group.

VAS score in the immediate postoperative period was significantly lower in patients who received TAP block except at 1 and 3 hours postoperative (**Table 3**).

Table (3): Postoperative VAS scores in both groups.

Time duration P value	GA	TAP
Significance	Mean±SD	Mean±SD
0 time(After recovery) <0.05*	4.9±1.4	3.8±1.2
-30 Min <0.05*	5.1±1.2	4.0±1.3
-1hr 0.296	4.3±0.9	3.9±0.8
-2hrs <0.05*	4.2±0.7	3.6±0.9
-3hrs 0.481	3.8±1.6	3.6±0.8
-6hrs <0.001*	3.4±0.7	2.7± 0.5
-12hrs <0.001*	2.7±0.5	2.0±0.4
-24hrs <0.05*	1.6±0.2	1.4±0.3

Data are expressed as mean ± SD.

\*= significant to other group.

Postoperative pethidine requirement was significantly higher in GA group compared to TAP group (Table 4).

Table (4): Postoperative Pethidine Requirements

Pethidine requirements 24hrs(mg)	GA		TAP		P value
	Mean	SD	Mean	SD	Significance
	92.3	9.2	41.7	7.6	<0.001*

Data are expressed as mean ± SD.

\*= significant to other group.

### DISCUSSION

Our finding in this study demonstrated that TAP block before skin incision reducing intra-operative fentanyl requirements in comparison to placebo, this finding was concomitant with those of Sulgana et al,<sup>[16]</sup> in patients undergoing total abdominal hysterectomy where intraoperative fentanyl consumption significantly lower in patients receiving TAP block with 0.25% bupivacaine. Mukhtar and Khattak,<sup>[17]</sup> recorded that, TAP block with 0.5% bupivacaine in patients undergoing renal transplant recipients were significantly

decreasing intra-operative morphine requirements than GA without TAP block ( $0.4 \pm 1.2$  mg vs.  $9.3 \pm 1.4$  mg).

El-Dawlatly et al,<sup>[18]</sup> recorded that, intra-operative sufentanil consumptions were significantly lower in patients receiving TAB block with laparoscopic cholecystectomy than control group ( $8.6 \pm 3.5$  mcg vs.  $23.0 \pm 4.8$  mcg). Similar findings were reported in a study by Ra et al,<sup>[19]</sup> intra-operative remifentanil consumptions were significantly lower in patients receiving TAB block by either 0.5% or 0.25% bupivacaine in laparoscopic cholecystectomy.

The benefits of TAB block and other regional analgesic techniques were reduction in pain intensity, reduction in the postoperative stress response, decreasing side effects from analgesic drugs, improving patient comfort and good surgical outcome with reduction in postoperative morbidity.<sup>[20]</sup>

In the present study, we used pethidine as postoperative analgesia after TAH and its requirements was higher in GA group compared to TAP group. Although intravenous pethidine is a good post-operative analgesic drug but can lead to side effects such as nausea, vomiting, pruritus and respiratory depression.<sup>[21]</sup> Zhao et al,<sup>[22]</sup> reported that, Patients with TAP block required less morphine consumption during postoperative 24 hours than those who did not have the block.

The effectiveness of the TAP block in providing immediate postoperative analgesia was assessed and proved by lower VAS score, we demonstrate that the mean postoperative visual analog scale (VAS) pain scores in GA group over the first 24h postoperatively was higher compared to the transversus abdominis plane (TAP) block group, which was first demonstrated by Carney et al,<sup>[9]</sup> who found that, a significant lower postoperative pain scores up to 48 h and postoperative morphine requirements also decreased up to 48 h in patients receiving TAP block in total abdominal hysterectomy which correlated with our finding. Those findings are also consistent with McDonnell et al,<sup>[8]</sup> who found that, the TAP block in patients undergoing surgery via a midline abdominal wall incision were reduce postoperative pain scores with effective and prolonged postoperative analgesia and reduced postoperative opioid requirements both at rest and on movement.

Sulgana et al,<sup>[19]</sup> who reported, a significantly lower post-operative VAS scores and prolonged postoperative analgesia in patients who received TAP block than control group (290 min vs. 16 min). Sharma et al,<sup>[23]</sup> also found that, TAB block in patients undergoing major abdominal surgery was improved VAS score in first post-operative 24 h. Petersen et al,<sup>[14]</sup> also

found that, a significant postoperative pain scores in ultrasound guided bilateral TAP block in patients undergoing laparoscopic and also Zhao et al,<sup>[22]</sup> found that, the pain was reduced at 2 h after surgery up to 24 h in TAP group when compared to control group.

In our study, TAB block prolonged the Time to the first postoperative using of analgesic drugs (112 min vs. 23 min). McDonnell et al,<sup>[15]</sup> recorded that, TAP block with 0.5% lignocaine in patient undergoing cesarean section produced effective post-operative analgesia and prolonged the Time to the first postoperative using of analgesic drugs for 4-6 h.

A single-shot TAP block technique produces effective analgesia and Reduce postoperative analgesic requirements up to 24 hours. The reasons for the prolonged duration of analgesic effect after single-shot TAP block may related to relatively poorly vascularized this area of block so drug clearance may be delayed and may be due to prolonged action of the amide local anesthetic drug (bupivacaine).<sup>[9]</sup>

In the current study, intra-operative heart rate and mean blood pressure were significantly higher in patients receiving GA compared to TAP block after surgical skin incision but non significant at all other time points. These results were similar to the results that obtained by Bhattacharjee et al<sup>[24]</sup> and Sulgana et al.<sup>[19]</sup>

Incidence of postoperative nausea-vomiting was non significant in both groups and no manifestation of local anesthetic drug toxicity or other side effects. These results were similar to the results that obtained by Sulgana et al.<sup>[16]</sup>

## CONCLUSION

Pre-incisional bilateral Ultrasound guided TAP block provides safe and potent intra and postoperative analgesia, reduces intra and post-operative analgesic requirements and less hemodynamic responses to surgical stimuli with minimal adverse effects after total abdominal hysterectomy.

## REFERENCES

1. Kehlet H, Holte K. Effect of postoperative analgesia on surgical outcome. *Br J Anesthesia* 2001; 87(1): 62–72.
2. Kehlet H. Surgical stress: the role of pain and analgesia *Br J Anesthesia* 1989; 63(2): 189–95.
3. White PF. The changing role of non-opioid analgesic techniques in the Management of postoperative pain. *Anesth Analg* 2005; 101(5): 5–22.
4. Rafi AN. Abdominal field block: a new approach via the lumbar triangle. *Anaesthesia* 2001; 56(10): 1024–6.
5. Niraj G, Kelkar A, Jeyapalan I, Graff-Baker P, Williams O, Darbar A. Comparison of analgesic efficacy of subcostal transversus abdominis plane blocks with epidural analgesia following upper abdominal surgery. *Anaesthesia* 2011; 66(6): 465–71.
6. Netter FH. Abdomen posterolateral abdominal wall. In: Netter FH, ed. *Atlas of human anatomy summit*. New Jersey, USA: The Ciba-Geigy Corporation, 1989; 4:230–40.
7. Griffiths JD, Middle JV, Barron FA, Grant SJ, Popham P.A, Royse CF. Transversus abdominis plane block does not provide additional benefit to Multimodal analgesia in gynecological cancer surgery. *Anesthesia* 2010; 111(3): 797–801
8. McDonnell JG, O'Donnell B, Curley G, Heffernan A, Power C, Laffey JG. The analgesic efficacy of transversus abdominis plane block after abdominal surgery: A prospective randomized controlled trial. *Anesth Analg* 2007; 104:193-7.
9. Carney J, Finnerty O, Rauf J, Curley G, McDonnell JG, Laffey JG. Ipsilateral transversus abdominis plane block provides effective analgesia after appendectomy in children: A randomized controlled trial. *Anesth Analg* 2010; 111:998-1003.
10. O'Donnell BD, McDonnell JG, McShane AJ. The transverses abdominis plane (TAP) block in open retropubic prostatectomy. *Reg Anesth Pain Med* 2006; 12:31-91.
11. Aveline C, Le Hetet H, Le Roux A, Vautier P, Cognet F, Vinet E. Comparison between ultrasound-guided transverses abdominis plane and conventional ilioinguinal/iliohypogastric nerve blocks for day-case open inguinal hernia repair. *Br J Anaesth* 2011; 106:380-6.
12. McDonnell JG, Curley G, Carney J, Benton A, Costello J, Maharaj CH, et al. The analgesic efficacy of transversus abdominis plane block after cesarean delivery: A randomized controlled trial. *Anesth Analg* 2008; 106:186-91.
13. Lancaster P, Chadwick M. Liver trauma secondary to ultrasound guided transversus abdominis plane block. *Br J Anaesthesia* 2010; 104:509–10.
14. Walter EJ, Smith P, Albertyn R, Uncles DR. Ultrasound imaging for transverses abdominis blocks. *Anaesthesia* 2008; 63(2):211.
15. Hebbard P. Subcostal transversus abdominis plane block under ultrasound guidance. *Anesth Analg* 2008; 106(2):674.
16. Sulagna B, Manjushree R, Tapas G, Souvik M, Amitava L. Analgesic efficacy of transversus abdominis plane block in providing effective perioperative analgesia in patients undergoing total abdominal hysterectomy: A randomized controlled trial. *Journal of Anaesthesiology Clinical Pharmacology*. Jan 2015; 197 (34): 203.52.
17. Mukhtar K, Khattak I. Transversus abdominis plane block for renal transplant recipients. *Br J Anaesth* 2010; 104:663-4.
18. El-Dawlatly AA, Turkistani A, Kettner SC, Machata AM, Delvi MB, Thallaj A, et al. Ultrasound-guided transversus abdominis plane block: Description of a new technique and comparison with conventional systemic analgesia during laparoscopic cholecystectomy. *Br J Anaesth* 2009; 102:763-7.
19. Ra YS, Kim CH, Lee GY, Han JI. The analgesic effect of the ultrasound-guided transverse abdominis plane block after laparoscopic cholecystectomy. *Korean J Anesthesiol* 2010; 58:362-8.



20. Capdevila X, Barthelet Y, Biboulet P, Ryckwaert Y, Rubenovitch J, Athis F. Effects of Perioperative analgesic technique on the surgical outcome and duration of rehabilitation after major knee surgery. *Anesthesiology* 1999; 91: 8–15.
21. Stanley G, Appadu B, Mead M, Rowbotham DJ. Dose requirements, efficacy and side effects of morphine and pethidine delivered by patient-controlled analgesia after gynaecological surgery. *Br J Anaesth* 1996; 76: 484–6.
22. Zhao X, Tong Y, Ren H, Ding XB, Wang X, Zong JY, et al. Transversus abdominis plane block for postoperative analgesia after laparoscopic surgery: a systematic review and meta-analysis. *Int J Clin Exp Med*. 2014; 7(9):2966-75.
23. Sharma P, Chand T, Saxena A, Bansal R, Mittal A, Shrivastava U. Evaluation of postoperative analgesic efficacy of transversus abdominis plane block after abdominal surgery: A comparative study. *J Nat Sci Biol Med* 2013; 4:177-80.
24. Bhattacharjee S, Ray M, Ghose T, Maitra S, Layek A: Transversus abdominis plane block in abdominal hysterectomy, *Journal of Anesthesiology Clinical Pharmacology*, July-September 2014; 30(3):391-396.