



Manuscript ID ZUMJ-2005-1839 (R2)
DOI 10.21608/zumj.2020.29297.1839

ORIGINAL ARTICLE

EFFECT OF NITRIC OXIDE IN CHRONIC EXPERIMENTAL TOXOPLASMA GONDII INFECTION: HISTOPATHOLOGICAL AND HISTOCHEMICAL STUDY

Marwa Omar¹, Beessa El-Sayed Abaza¹, Esraa Saleh Ibrahim Mousa¹, Hayam Elsayed Hassan Rashed², Tahani I. Farag¹
Department of Medical Parasitology¹ and Pathology², Faculty of Medicine, Zagazig University, Egypt.



Corresponding Author
Tahani Ismail Farag ,
E mail:
tahaniabdelkhalik
@yahoo.com

Submit Date 2020-05-12
Revise Date 2020-07-03
Accept Date 2020-07-16

ABSTRACT

Aim of the work: To evaluate the histopathological alterations and immunohistochemical pattern in chronic *Toxoplasma gondii* infection, and to evaluate the role aminoguanidine in chronic experimental toxoplasmosis.

Subjects and methods: This study was carried out on 48 laboratory-bred male Swiss albino mice which were divided into 4 groups (non-infected control; infected control; infected and treated with spiramycin; infected and treated with aminoguanidine). The effect of the used drugs was assessed using parasitological, histopathological and immunohistochemical approaches.

Results: There was highly significant ($P < 0.001$) reduction in the number of brain cysts in spiramycin treated group. On the other hand, after the administration of aminoguanidine, the number of brain cysts significantly increased ($P < 0.001$). The lethal effect of spiramycin on *Toxoplasma gondii* helped to reduce the pathological changes associated with the presence of the parasite in both cerebral and cardiac tissues. However, there was a difference in the effect of aminoguanidine on the infected organs. In cerebral tissues, aminoguanidine caused a marked increase in inflammatory infiltration, as well as the persistence of brain gliosis. Yet, in the cardiac tissues, it induced resolution of various pathological changes. Although spiramycin didn't affect inducible nitric oxide synthase (iNOS) expression, weak expression of the enzyme was exhibited after aminoguanidine treatment.

Conclusion: Nitric oxide is essential for understanding the host-parasite relationship. It has important immunomodulatory roles in chronic *Toxoplasma gondii* infection. The use of iNOS selective inhibitors like AG helps to reduce the pathological changes heart tissues but not in brain tissues in *Toxoplasma* infection.

Keywords: Toxoplasmosis, Aminoguanidine, Histopathology, Immunohistochemical, Spiramycin, iNOS.

INTRODUCTION

Toxoplasmosis is a cosmopolitan zoonosis, approximately one-third of the world's population is infected with *Toxoplasma gondii*, and thus this parasite is one of the best adapted to infect humans ^[1]. Man gets infection by ingesting undercooked meat containing tissue cysts or from contamination with oocysts in faeces of cats ^[2]. Although 90% of cases are asymptomatic or benign, it is regarded as an important health problem in pregnant women

due to complications of transmitting the parasite to the fetus. Also, in immunocompromised patients, primary or reactivated toxoplasmosis can cause serious health problems and risk of death ^[3].

A balance between oxidants and antioxidant exists under physiological conditions. However, even small changes in oxidant or/and antioxidant levels may interrupt its balance and lead to oxidative stress ^[4]. The central nervous system is particularly susceptible to oxidative

stress (OS) [5]. *Toxoplasma*-mediated oxidative stress (OS) is suggested to take part in the mechanisms of neuropathology and neurodegeneration [6].

Reactive oxygen species (ROS) can be used by the immune system as a way to attack and kill the pathogen. However, their production can cause severe damage to biological molecules such as carbohydrates, nucleic acid, lipid and protein [7]. The functional role of nitric oxide (NO) in the immune system is controversial. Therefore, the involvement of NO in parasitic infections is currently under debate and still requires more investigations [8].

Aminoguanidine (AG) is an inducible nitric oxide synthase (iNOS) inhibitor [9]. It has been used in many experimental studies to evaluate its effect upon the parasitic load and the inflammatory process, it was used in toxocariasis, filariasis, hymenolepiasis and strongyloidiasis to investigate the influence of the inhibition of the NO production [10].

Immuno-histochemistry is widely used in basic research to understand the distribution and localization of biomarkers and differentially expressed proteins in different parts of biological tissues. Visualizing an antibody-antigen interaction can be accomplished in several ways. In the most common instance, an antibody is conjugated to an enzyme, such as peroxidase, that can catalyze a colour-producing reaction [11]. In this research, we aimed to evaluate the role of aminoguanidine in chronic experimental *Toxoplasma gondii* infection, through the study of histopathological alterations and immuno-histochemical patterns.

MATERIALS AND METHODS

The current study was carried out at the Parasitology Department, Faculty of Medicine, Zagazig University, Egypt. The study was approved by the research ethical committee of Faculty of Medicine, Zagazig University. The whole experiment complied with the ARRIVE guidelines (Animal Research: Reporting of *In Vivo* Experiments) and was carried out in accordance with the U.K. Animals.

Fourty eight laboratory-bred male Swiss albino mice, 10 weeks old, each weighing 20-25 g

were selected from the animal house of the Faculty of Science, Zagazig University. They were housed in plastic cages with white wood chips for bedding, fed by commercial complete food mixture and tap water for drinking, and maintained under controlled conditions of lighting and temperature. Four groups of mice (12 mice each) were included in the study:

- **Group (I):** non- infected control group.
- **Group (II):** infected control group.
- **Group (III):** infected and treated with spiramycin at a dose of 12.5 mg/ kg/ day [12]. The drug was provided in powder form and prepared daily as liquid suspensions; after half an hour of sonication, the homogenized suspensions were administered orally to mice via tube feeding. It was administrated daily at a fixed hour for 10 days.
- **Group (IV):** infected and received aminoguanidine at a dose of 50 mg/kg/ day orally [13]. Aminoguanidine in the form of aminoguanidine bicarbonate as a white powder (Sigma Aldrich, Cairo, Egypt) was dissolved in saline and administrated orally for two weeks. The study groups were given the drugs 8 weeks post-infection.

Infection with avirulent strain of *T. gondii* (Me49) was initiated by oral administration of 10 cysts in 0.1 ml of diluted brain suspension using a 19-gauge gavage needle. The mice were sacrificed 10 weeks after the infection by cervical dislocation. The abdominal skin was sterilized by 70% methyl alcohol, then incised, the peritoneum was grasped by multi-toothed sterile forceps and opened for obtaining the heart. The head was opened to get the brain which was removed under sterile conditions and homogenized with 1ml of normal saline by passing through 23 gauge needle. The effect of the used drugs was evaluated using parasitological, histopathological and immunohistochemical measures:

1- Parasitological assessment.

Quantification of Brain Cysts:

One half of the brain from each of the experimentally infected mice was used for evaluation of the cyst burden. The total number of cysts per mouse brain was determined by

placing 2 drops (20 μ l each) of brain homogenate onto microscopic slides and counted under light microscopy at X40 magnification. The count was then multiplied by 25 to obtain the number of tissue cysts per 1 ml (1000 μ l) of brain suspension [14]. Then, the mean cysts number in each group was calculated.

2- Histopathological assessment:

Cerebral and cardiac tissues were fixed in 10% neutral buffered formalin solution. Then stained with hematoxylin and eosin and examined under light microscopy for histopathological studies [15].

3-Immunohistochemical assessment [16]:

Serial sections from the cerebral and cardiac blocks were submitted for immune histochemical staining with antibodies used against iNOS; anti-iNOS (dilution 1: 50; Santa Cruz Biotechnology). The indirect streptavidin-biotin immunoperoxidase staining technique was used in this study. Cytoplasmic immunostaining for iNOS was used to measure the expression of iNOS marker. It was semi-quantitatively scored as follows: 0, negative; 1, weak (<10% expression of cells); 2, moderate (10–20% expression of cells); and 3, strong (expression in >50%).

Ethical consideration: Mice were reared and sacrificed according to the protocol of The Institutional Animal Care and Use Committee according to Zagazig University (ZU-IACUC) for Animal Use in Research and Teaching.

Statistical methods: The data were entered, checked, verified and analyzed using Statistical Package for the Social Sciences "SPSS version 22 [17].

RESULTS

I.Parasitological results:

There was highly significant ($P<0.001$) reduction in the number of brain cysts in spiramycin treated group (GIII), when compared to infected control group (GII) (Table 1). On the other hand, in (GIV), after administration of aminoguanidine, the number

of brain cysts significantly increased ($P<0.001$) (Table 2).

2. Histopathological results:

I. Brain Sections:

Various pathological changes were reported in the infected group (GII). Inflammatory infiltration of meninges and gliosis were reported in (GII) as shown in Figures (1) and (2) respectively. Resolution of pathological changes was noticed after treatment with spiramycin in (GIII). For example, inflammatory infiltration decreased. Moreover, there was reduction of cyst number with degeneration of existing cysts (Fig. 3). After treatment with AG in (GIV), inflammatory infiltration markedly increased and gliosis was not improved.

II. Heart sections:

In infected group (GII) mice, several pathological changes were reported like; lymphocytic infiltration (Fig. 4) and inter-fibrillar oedema (Fig. 5). Resolution of pathological changes was observed in (GIII) and (GIV) after administration of spiramycin and AG respectively. In both groups (GIII) and (GIV), there was reduction of inflammatory infiltration (Figs. 6 and 7).

3. Immunohistochemical results:

I. Brain Sections:

In infected groups (treated and control), iNOS expression was observed with different intensities. In (GII), iNOS expression was moderate (Fig. 8). After administration of spiramycin in (GIII), iNOS expression was similar to that of infected group (GII), (Fig.9). In (GIV) after aminoguanidine administration, weak iNOS expression was demonstrated (Fig. 10).

II. Heart sections:

Moderate iNOS expression was reported in heart tissues of the infected group (GII) (Fig. 11). In G (III) after spiramycin administration, iNOS expression was similar to that of the infected group. On the other hand, (GIV) exhibited weak iNOS expression (Fig. 12).

Table (1): Comparison between mean values of brain cysts number in (GII) and (GIII):

Parameter	Group II	Group III	T-Test	P-value
Cyst number:				
Mean ± SD	420	200		
Range	420±15 400-470	200±10 180-220	29	0.000*

Table (2): Comparison between mean values of brain cysts number in (GII) and (GIV):

Parameter	Group II	Group IV	T-Test	P-value
Cyst number:				
Mean ± SD	420	550	-12	0.000*
Range	420±15 400-470	550±20 500-620		

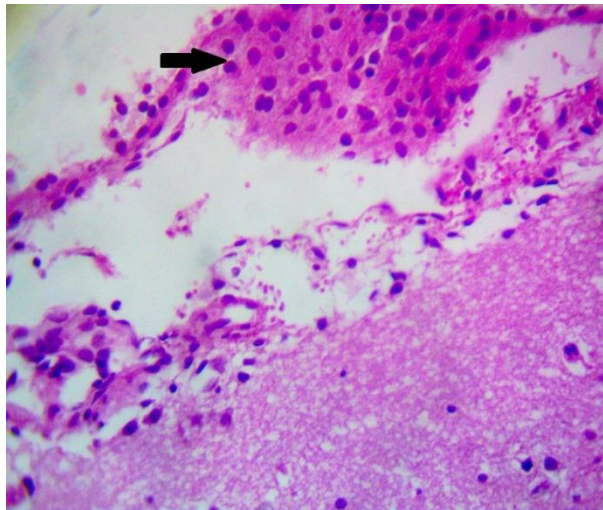


Fig. (1): Brain section of infected group (GII) showing inflammatory infiltration of meninges (H&E stain, X 400).

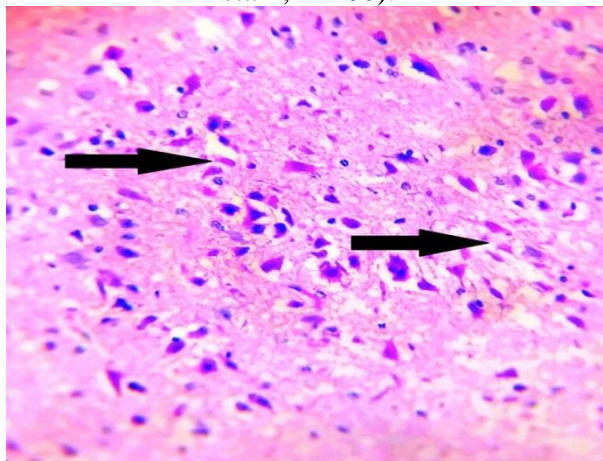


Fig. (2): Brain section of infected group (GII) showing gliosis (H&E stain, X 400).

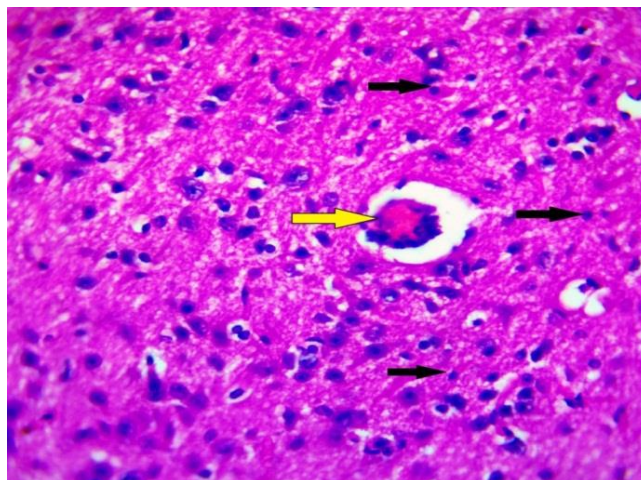


Fig. (3): Brain section of spiramycin treated group (GIII) showing mild inflammatory infiltrate (black arrows) and degenerated *Toxoplasma* cyst (yellow arrow) (H&E stain, X 400).

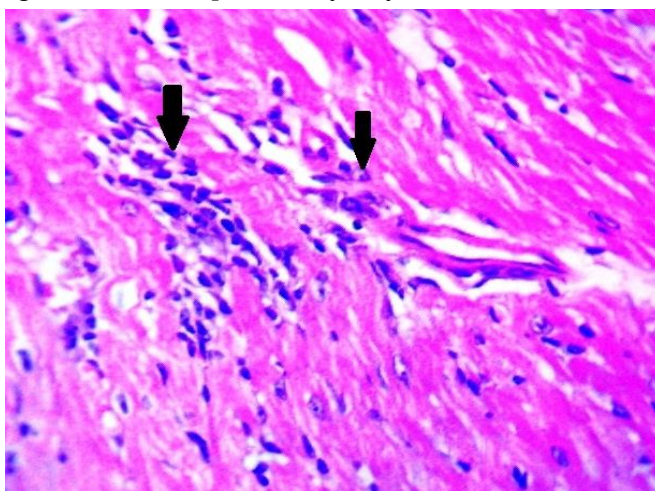


Fig. (4): Heart section of infected group (GII) showing moderate inflammatory cellular infiltration (black arrow) (H&E stain, X 400).

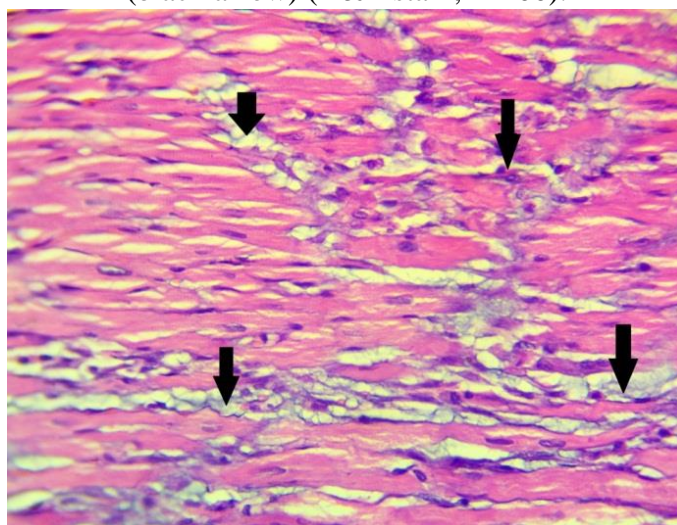


Fig. (5): Heart section of infected group (GII) showing inter-fibrillar oedema (H&E stain, X 400).

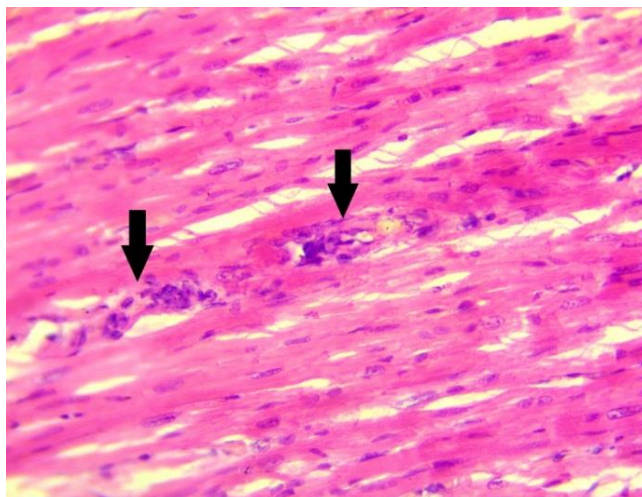


Fig. (6): Heart section of spiramycin treated group (GIII), showing mild inflammatory cellular infiltration (black arrows) (H&E stain X 400).

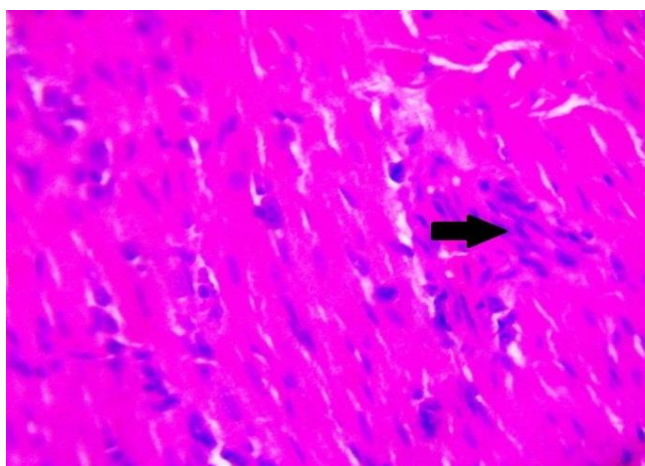


Fig. (7): Heart section of aminoguanidine treated group (GIV) showing mild lymphocytic inflammatory cellular infiltration (black arrows) (H&E stain, X 400).

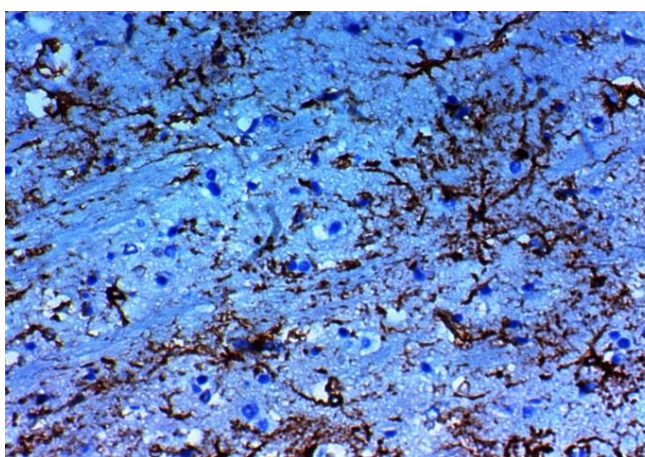


Fig. (8): Brain section of infected group (GII) showing moderate iNOS expression (IHC stain, X 400).

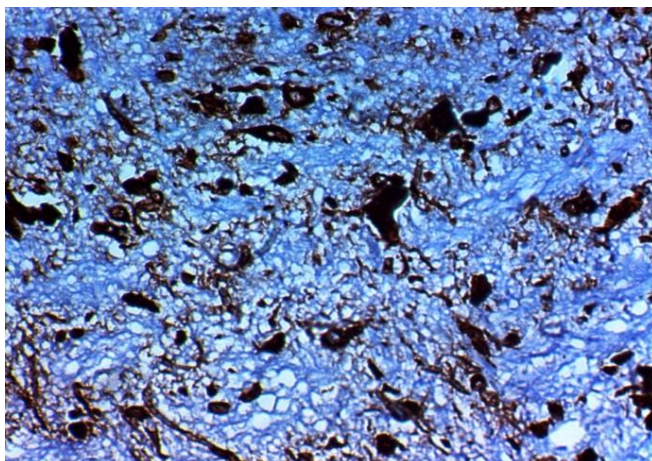


Fig. (9): Brain section of spiramycin treated group (GIII) showing moderate iNOS expression (IHC stain, X 400).

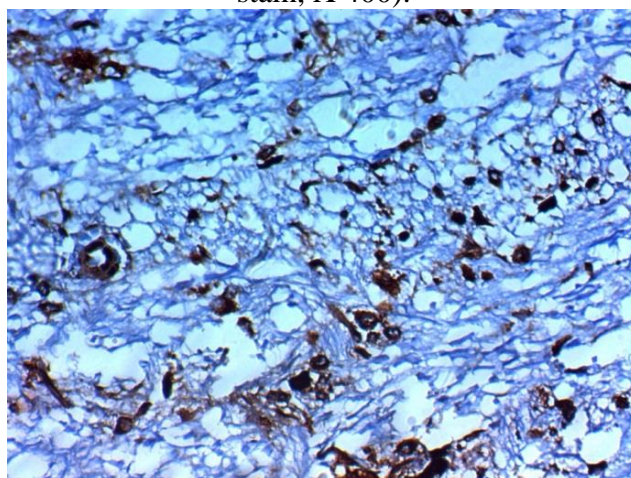


Fig. (10): Brain section of aminoguanidine treated group (GIV) showing weak iNOS expression (IHC stain, X 400).

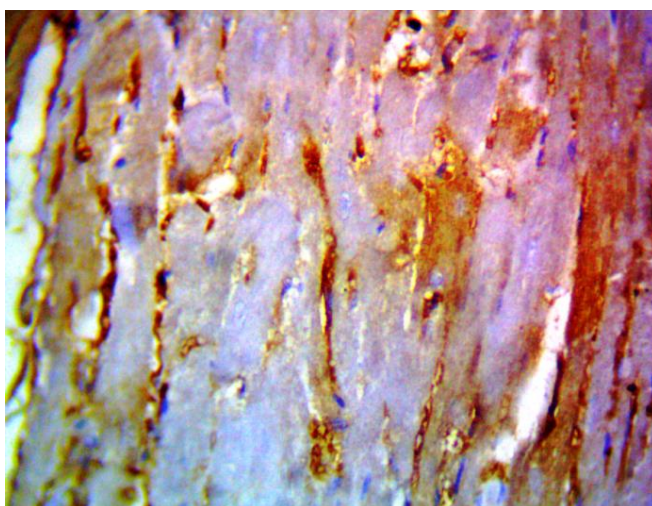


Fig. (11): Heart section of the infected group (GII) showing moderate iNOS expression (IHC stain, X 400).

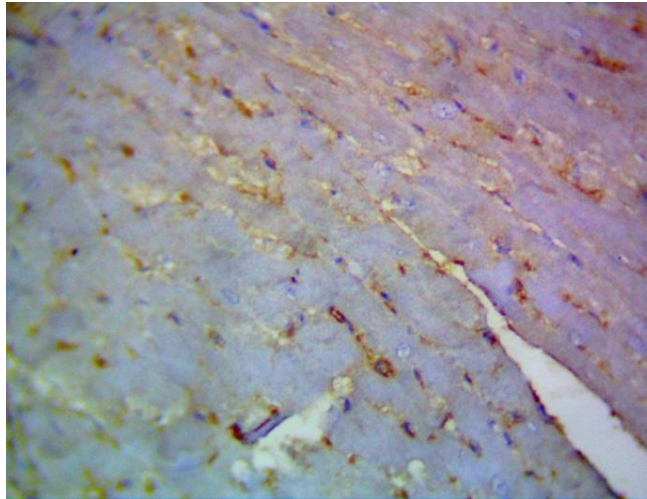


Fig. (12): Heart section of aminoguanidine treated group (GIV), showing weak Inos expression (IHC stain, X 400).

DISCUSSION

Toxoplasma gondii is an important intracellular parasite of humans and animals which causes life threatening condition in immunocompromised persons [18]. About 30–50% of the world population is infected with the parasite, and it is the most prevalent infection among humans [19]. It is transmitted predominantly by ingestion of oocysts from contaminated food or water, ingestion of the tissue cysts or congenitally from mother to foetus. Other methods of transmission include blood transfusion and haematopoietic stem cell or solid organ transplantation [20].

In the present study, there was highly significant ($P < 0.001$) reduction in the mean number of *Toxoplasma* cysts in brains of mice treated with spiramycin (GIII) compared with infected untreated group (GII) as shown in (Tables 1). These observations are in agreement with **Grujić et al.** [21] who proved that spiramycin reduced cyst numbers in both acute and chronic murine infections. On the other hand, in (GIV) after intake of aminoguanidine, mean number of brain cyst increased compared to infected control group (GII) with highly significant difference ($P < 0.001$) (Tables 2). These finding were consistent with that of **Schlüter et al.** [22] who found that AG treatment markedly increased the number of brain cysts in *T. gondii* infected mice.

In the current work, brain tissues of infected group (GII) showed presence of inflammatory cellular infiltrate in meninges and gliosis (Figs. 1 and 2). These observations are in agreement with **El-Temsahy et al.** [23] who observed that brains of untreated infected mice in chronic stage showed *toxoplasma* cysts enclosed with chronic inflammatory cells. In (GIII), after administration of spiramycin, resolution of pathological changes was noticed besides degeneration of the existing cysts (Fig. 3). On the other hand, in (GIV), after treatment with AG, the degree of inflammatory infiltration increased. Similar results were demonstrated by **Scharton-Kersten et al.** [24] who found that in mice chronically infected with *Toxoplasma gondii*, iNOS inhibitor L-NMMA (NG-monomethyl-L-arginine) showed reactivation of infection with increased inflammatory changes in brain tissues. In contrast to previous observation, **Kro'ncke et al.** [25] observed that the control of intra-cerebral persisting toxoplasmosis in the latent phase of the infection does not require iNOS activity.

In the heart sections of (GII) mice, there were remarkable pathological changes like; lymphocytic infiltration (Fig. 4) and inter-fibrillar edema (Fig. 5). Improvement of such pathological changes was observed in (GIII) and (GIV) after administration of spiramycin and AG respectively (Figs. 6 and 7). **Cigremis**

et al. [26] confirmed that aminoguanidine has beneficial role in reducing the degree of inflammatory cellular infiltration and in reversing severe myocardial fibrosis.

In the brain sections of the infected group (GII), iNOS expression was moderate (Fig. 8). In (GIII), after spiramycin administration iNOS expression was similar that of infected group (GII) (Fig. 9). Labro [27] demonstrated that spiramycin does not modify oxidant production by neutrophils. On the other hand, in (GIV), weak iNOS expression was detected (Fig.10). Similar results were obtained by Schlüter et al. [22] who observed that mice infected with toxoplasmosis and treated with 1-N6-iminoethyl-lysine (1-NIL) iNOS inhibitor, showed suppressed iNOS expression in brain tissues. In our research, the heart sections of (GII) mice, exhibited moderate iNOS expression (Fig. 11). After AG administration, iNOS expression was markedly lowered (Fig. 12). The effect of aminoguanidine in reducing iNOS expression was in agreement with Kang et al. [28]

CONCLUSION

Spiramycin was effective in treatment of toxoplasmosis as it caused marked reduction in brain cysts number. On the other hand, AG significantly increased the number of brain cysts. Spiramycin had no effect on iNOS expression while, AG had a role in inhibiting the enzyme.

Declaration of interest:

The authors report no conflicts of interest. The authors alone are responsible for the content and writing of the paper.

Funding information:

None declared

REFERENCES

- [1] Remington J , Klein J , Wilson C , Baker C . Infectious disease of the fetus and newborn infant, 2011; 7th ed. Philadelphia: Elsevier Saunders.
- [2] Jongert E, Roberts C , Gargano N, Förster-Waldl E, Petersen E. Vaccines against *Toxoplasma gondii*: challenges and opportunities. Mem Inst Oswaldo Cruz 2009; (104): 252-266.
- [3] Atilla A, Aydin S, Demirdöven A, Kiliç S. Severe toxoplasmic hepatitis in an immunocompetent patient. Jpn J Infect Dis 2015; (68): 407-409.
- [4] Sibille P, Tliba O, Boulard C. Early and transient cytotoxic response of peritoneal cells from *Fasciola hepatica*-infected rats. Veterinary research 2004; 35(5): 573-584.
- [5] Afifi M, Jiman-Fatani A, Al-Rabia M, Al-Hussainy N, El Saadany S, Mayah W. Latent Toxoplasmosis Might Provoke a Local Oxidative Stress That Triggers the Development of Bipolar Disorder J Microsc. Ultrastruct 2018; (3):139-144.
- [6] Dincel G, Atmaca H. Nitric oxide production increases during *Toxoplasma gondii* encephalitis in mice. Experimental parasitology 2015; (156): 104-112.
- [7] Segal A. How neutrophils kill microbes. Annual Review of Immunology 2005; (23): 197-233.
- [8] Nahrevanian H. Involvement of nitric oxide and its up/down stream molecules in the immunity against parasitic infections. Braz J Infect Dis 2009; (6):440-8.
- [9] Alipour M, Adineh F, Mosatafavi H, Aminabadi A, Monirinasab H, Jafari M. Effect of chronic intraperitoneal aminoguanidine on memory and expression of bcl-2 family genes in diabetic rats. Can J Physiol Pharmacol 2016; (94): 669–75.
- [10] Muro A, Perez-Arellano J. Nitric Oxide and Respiratory Helminthic Diseases. J Biomed Biotechnol 2010; (10): 1-8.
- [11] Uzêda R, Schares G, Ortega-Mora L, Madruga C, Aguado-Martinez A, Corbellini L, Driemeier D, Gondim L. Combination of monoclonal antibodies improves immuno-histochemical diagnosis of *Neospora caninum*. Vet Parasitol 2013; 197(3-4):477-86.
- [12] Filice G, Pomeroy C. Effect of clindamycin on pneumonia from reactivation of *Toxoplasma gondii* infection in mice. Antimicrob Agents Chemother 1991; (35):780-782.
- [13] Mahmoud M, Zakaria S, Fahmy A. Can Chronic Nitric Oxide Inhibition Improve Liver and Renal Dysfunction in Bile Duct Ligated Rats? Advances in Pharmacological Sciences 2015; 1–7.
- [14] Ole A. OIE Manual of diagnostic tests and vaccines for terrestrial animals, Toxoplasmosis 2008; 1(6): 1286.
- [15] Tanaka S, Nishimura M, Ihara F, Yamagishi J, Suzuki Y, Nishikawa, Y. “Transcriptome

- analysis of mouse brain infected with *Toxoplasma gondii*,” Infection and Immunity 2013; 81(10): 3609–3619.
- [16] Soo R, Putti T, Ta Q, Goh B, Lee K, Kwok-Seng L, Tan L, Hsieh W. Over expression of cyclooxygenase-2 in nasopharyngeal carcinoma and association with epidermal growth factor receptor expression. Arch Otolaryngol Head Neck Surg 2005; (131):147–152.
- [17] Armonk N. IBM SPSS Statistic for windows version 22.0. 2013.
- [18] Bando H, Lee Y, Sakaguchi N, Pradipta A, Ma J, Tanaka S, Cai Y, Liu J, Shen J, Nishikawa Y, Sasai M, Yamamoto M. Inducible nitric oxide synthase is a key host factor for *Toxoplasma* GRA15-dependent disruption of the gamma interferon-induced antiparasitic human response. mBio 2018; (9):e01738-18.
- [19] Flegr J, Prandota J, Sovičková M, Israili Z. Toxoplasmosis: a global threat; correlation food: analysis and control. Microbiol. Spectrum 2014; 4(4): PFS-0011-2015.
- [20] Sroka S, Bartelheimer N, Winter A, Heukelbach J, Ariza L, Ribeiro H, Liesenfeld O. Prevalence and risk factors of toxoplasmosis among pregnant women in Fortaleza, Northeastern Brazil. The American journal of tropical medicine and hygiene 2010, 83(3): 528-533.
- [21] Grujić, J.; Djurković-Djaković, O.; Nikolić, A.; Klun, I. and Bobić, B. (2005): Effectiveness of spiramycin in murine models of acute and chronic toxoplasmosis. International journal of antimicrobial agents, 25 (3): 226-230.
- [22] Schlüter D, Deckert-Schlüter M, Lorenz E, Meyer T, Röllinghoff M, Bogdan C. Inhibition of Inducible Nitric Oxide Synthase Exacerbates Chronic Cerebral Toxoplasmosis in *Toxoplasma gondii*-Susceptible C57BL/6 Mice But Does Not Reactivate the Latent Disease in *T. gondii*-Resistant BALB/c Mice. J Immunol 1999; 162 (6) 3512-3518.
- [23] El-Temsahy M, El Kerdany E, Eissa M, Shalaby T, Talaat I, Mogahed N. The effect of chitosan nanospheres on the immunogenicity of *Toxoplasma* lysate vaccine in mice. J Parasit Dis 2016; 40(3):611–626.
- [24] Scharton-Kersten T, Yap G, Magram J, Sher A. Inducible nitric oxide is essential for host control of persistent but not acute infection with the intracellular pathogen *Toxoplasma gondii*. J Exp Med 1997; 185 (7):1261-1273.
- [25] Kro'ncke K, Fehsel K, Kolb-Bachofen V. Inducible nitric oxide synthase in human diseases. Clin. Exp. Immunol 1998; (113):147.
- [26] Cigremis Y, Parlakpınar H, Polat A, Colak C, Ozturk F, Sahnı E, Ermis N, Acet A. Beneficial role of aminoguanidine on acute cardiomyopathy related to doxorubicin-treatment. Mol Cell Biochem 2006; (1-2):149-54.
- [27] Labro M. Pharmacology of Spiramycin : A Comparison with Other Macrolides. Drug Investigation 1993; 6 (Suppl. I): 15-28.
- [28] Kang K, Lee G, Lee J, Choi I, Shin D, Lee Y. Effects of iNOS inhibitor on IFN- γ production and apoptosis of splenocytes in genetically different strains of mice infected with *Toxoplasma gondii*. The Korean j parasitol 2004; 42(4): 175.

How to Cite

Omar, M., Abaza, B., Mousa, E., Rashed, H., Farag, T. EFFECT OF NITRIC OXIDE IN CHRONIC EXPERIMENTAL TOXOPLASMA GONDII INFECTION: HISTOPATHOLOGICAL AND HISTOCHEMICAL STUDY. Zagazig University Medical Journal, 2021; (938-947): -. doi: 10.21608/zumj.2020.29297.1839