

## Original Article

## Outcome of Local Flaps in Mid and Lower Face Reconstruction.

Mohammed B. Alnassir<sup>1</sup>, Mohammed H. Abdelaal<sup>1</sup>, Alaa M. Nabil<sup>1</sup>, Ahmed M. Ismaeel<sup>1</sup>

Plastic &amp; Reconstructive Surgery Department, Faculty of Medicine, Zagazig University, Egypt

## Corresponding author

Mohammed Bachir Alnassir

## E-mail:

[mohamadnasser1978@gmail.com](mailto:mohamadnasser1978@gmail.com)

Submit Date 2021-01-15

Revise Date 2021-03-23

Accept Date 2021-04-28

## ABSTRACT

**Background:** Different reconstructive approaches have been introduced over last decades for management of facial defects. Local flaps, whenever possible, may be an ideal solution for some defects. The aim of our study is evaluation of the outcomes of different local flaps in reconstruction of mid and lower facial defects.

**Methods:** This study was a prospective, non-randomized and uncontrolled trial recruiting twenty patients admitted between December 2017 to June 2018 at plastic surgery unit, Zagazig University Hospitals complaining of facial defects post trauma and tumors excision and trauma to mid- and lower face regions due to multiple etiologies. Twenty patients were admitted to plastic surgery unit complaining of facial skin tumors and post-traumatic mid and lower facial defect.

**Results:** The mean and standard deviation of age was 51 years  $\pm$  20.68 with minimum 9 years and maximum 77 years. In our study, there were 11 males (55%) and 9 females (45%). the relationship between patient satisfaction and outcome, there was statistically significant difference toward having good outcome and good verbal response ( $p = 0.006$ ). There was statistically significant deviation of outcome to be good or very good rather than poor or accepted despite presence of complication ( $p=0.002$ ). In order to examine the relationship between patient satisfaction and defect area there was no statistically significant difference both variables ( $p = 0.085$ ).

**Conclusion:** Meticulous selection of facial flap for every lesion is mandatory for gaining not only better results aesthetically but to protect patient's self-image, self-esteem and prevention of associated depression.

**Keywords:** Facial flaps, plastic surgery, mid-face, lower-face



## INTRODUCTION

Face contains many functional and expressive structures, so the restoration of facial defects considers of the huge challenge due to limitation of local tissues provided for repair [1]. For reconstructive results, the optimal goals for such defects require great care to restore the function of facial defects, size and location of the defect in the face, available donor site, the presence of skin tension lines and surgical closure techniques [2–5]. For the best results, surgeon should use local tissues to provide the best color and defect restoration [6]. Reconstruction of facial defects requires understanding of skin anatomy and physiology, careful analysis of the defect, a pleasing aesthetic outcome, facial symmetry and advanced principles of wound healing. The reconstruction options will depend largely on the location, size, and depth of the defect [7].

Different reconstructive techniques have been introduced over years for management of facial defects. Local flaps, whenever possible, may be an ideal solution for some defects [6].

The individual surgeon's judgment, experience, and familiarity with the various techniques and flaps ultimately influence the selection of reconstructive techniques [8].

Evolution in surgery has permitted the ever increasing capability to change the architecture of the face for reconstruction or aesthetic increment. Strategies for preoperative assessment and planning are necessary parallels to these surgical advances to achieve an optimal outcome. The surgeon involved in facial restoration and aesthetics must understand the complex relationships of the face to plan and execute the procedure most likely to produce the desired result [9].

Aim of our study is evaluation of the outcomes (patients' satisfaction, presence of complications, deglutition and verbal affection) of different local flaps in reconstruction of mid and lower facial defects.

### Methods

This study was a prospective, non-randomized and uncontrolled trial recruiting twenty patients admitted between December 2017 to June 2018 at plastic surgery unit, Zagazig University Hospitals complaining of facial defects post trauma and tumors excision and trauma to mid- and lower face regions due to multiple etiologies. Written informed consent was obtained from all participants, the study was approved by the research ethical committee of Faculty of Medicine, Zagazig University. The study was done according to The Code of Ethics of the World Medical Association (Declaration of Helsinki) for studies involving humans.

Twenty patients were admitted to plastic surgery unit complaining of facial skin tumors and post-traumatic mid and lower facial defect. Inclusion criteria included all patients with mid- and lower mild to moderate facial defect, non-advanced facial malignancy and absence of comorbidities. Exclusion criteria included patients with massive defect, advanced malignancies and presence of cardiac, neurological or respiratory comorbidities.

All patients underwent the followings; history of mechanism of injury, events leading up to the injury, time of occurrence, associated comorbidities, allergies and medications, full labs, plain x-ray of facial skeleton and designation of flap and selection of flap near the defect.

Regarding timing of surgery, facial repair was done within the first 8 hours of the initial insult. Repair of the wounds was done under general anesthesia in all cases.

Management all our patients were managed with local and regional flaps designed according to site and sizes of defects in skin, color, thickness, texture of the recipient of donor site and flap morbidity was recorded.

### Follow-up

Oral antibiotics were given in the first five days. Analgesia in the form of nonsteroidal were given according to patient need and patient condition. Principle of wound management after repair or reconstruction were applied, daily cleansing of the wound with saline solution, application of antibiotic creams then covering with sterile dressing, sutures were removed after six to seven days. Monitoring of the flap where done in the first day then daily till the removal of sutures. Color of the flaps were recorded (normal, blanched, or cyanosed). Although viability of the flap were decided using blanching test where

blanching occurs by fingertip pressure and refill within three second after release.

### Statistical Analysis

Data was analyzed using IBM SPSS advanced statistics version 25 (SPSS Inc., Chicago, IL). Numerical data were expressed as mean and standard deviation or median and range as appropriate. Qualitative data were expressed as frequency and percentage. Chi-square test was used to examine the relation between qualitative variables. For not normally distributed quantitative data, comparison between two groups was done using chi-Square t-test. A p-value < 0.05 was considered significant.

## RESULTS

### Demographic distribution

The mean and standard deviation of age was 51 years  $\pm$  20.68 with minimum 9 years and maximum 77 years. In our study, there were 11 males (55%) and 9 females (45%) [Figure 1]. Diabetes mellitus was present in only 4 cases and hypertension was present in only 2 cases. Regarding presence or absence of complications, only 2 cases developed infection at recipient site (nasal flap) while one case had had infection at donor site (old age with past medical history of uncontrolled DM). By using Mann Whitney t-test and Chi-square t-test, there was no statistically significant correlation between having good or poor outcome in a hand and age or sex in the other hand (0.408, 0.30) respectively.

### Etiology

Regarding etiology, only 5 cases (25%) were of trauma origin including a case was post-cleft lip repair. On the other side, 75% of cases were of tumorous origin (squamous cell carcinoma (2 cases), and finally 13 cases of basal cell carcinoma). Full description as stated well [Figure 2].

### Flaps Site

Our study involved mid and lower part of face. The distribution of defects were scattered throughout these areas under study. The [Table 2] illustrates the location of each defect.

### Size of defect

Defect was measured in length and width in mm. Size of defect has been measured by square centimeter. The mean, SD and median as plotted in the table below:

The flaps were classified into small, medium and large flaps. The small flap is for those who area was below 2 cm<sup>2</sup>, those between 2-4 cm<sup>2</sup> were regarded medium sized flaps, and large flaps are those above 5 cm<sup>2</sup> as in the following:

### Flap Type

In our study, different flap types were used according to defect surface area, site and severity of

the defect. In the bar chart below; full description of flaps type was used in our study.

**Study Outcomes**

In the table below, illustration of the patients' feedback regarding the surgical decision and the results of management obtained 3 months-postoperatively and was graded in five grades (poor, accepted, good, very good or excellent) where poor satisfaction is the least and excellent is the best. In general, 'good outcome' involved 80% of responses, the bad or poor outcome was present in no case. In order to examine the relationship between patient satisfaction and outcome, statistical analysis using Chi-square t-test showed that there was statistically significant difference toward having good outcome and good verbal response ( $p = 0.006$ ).

We consider poor and accepted are non-satisfied but good, very good and excellent result are satisfied [Table 3]. Satisfaction was measured by lekand scale (5) points.

By using Chi-square t-test to examine the presence of 'good' or 'bad' outcome in our study and presence of complication, there was statistically significant deviation of outcome to be good or very good rather than poor or accepted despite presence of complication ( $p=0.002$ ). In order to examine the relationship between patient satisfaction and defect

area, statistical analysis using Chi-square t-test showed that there was no statistically significant difference both variables ( $p = 0.085$ ).

In 70% of our cases there were no of complications. Scar was seen in 5% only while serious complications were seen in 20% of cases as seen in the table below.

The relationship between flap type and complication, statistical analysis using Chi-square t-test showed that there was no statistically significant difference between both variables ( $p = 0.490$ ). This can be best translated that complication can occur with any type of flap.

The relationship between flap type and complication has been examined using Chi-square t-test and showed that there was slight statistically significant difference between both variables ( $p = 0.0456$ ). This can be best explained that these complications can occur with specific type of flap as shown in the table. As regard patient satisfaction, young females were less satisfied than older females especially with large defects ( $<0.05$ ).

Our study outcome has been assessed by testing the possibility of deglutition and verbal affection of (L, M and N). It has been found that 20% of cases developed affection of verbal articulation or deglutition as in the pie chart

**Table 1: Location of defects**

	Frequency	Percent
Alar lobule	2	10.0
check lesion	1	5.0
dorsum and side of nose	1	5.0
Dorsum nose	2	10
lateral nasal side only	2	10.0
Lateral check	1	5.0
upper lip	2	10.0
lower lip	5	25.0
Right check	2	10
One nasal side (right)	2	10.0
<b>Total</b>	<b>20</b>	<b>100.0</b>

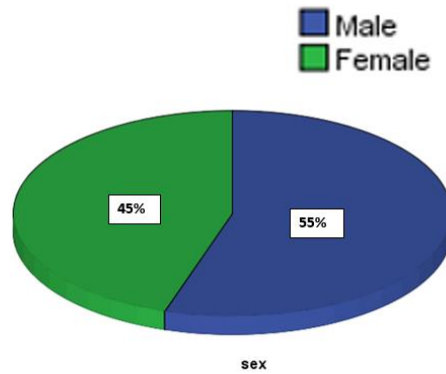
**Table 2: Flap size in cm<sup>2</sup>**

<b>Mean</b>	6.9
<b>SD</b>	2.78
<b>Median</b>	4

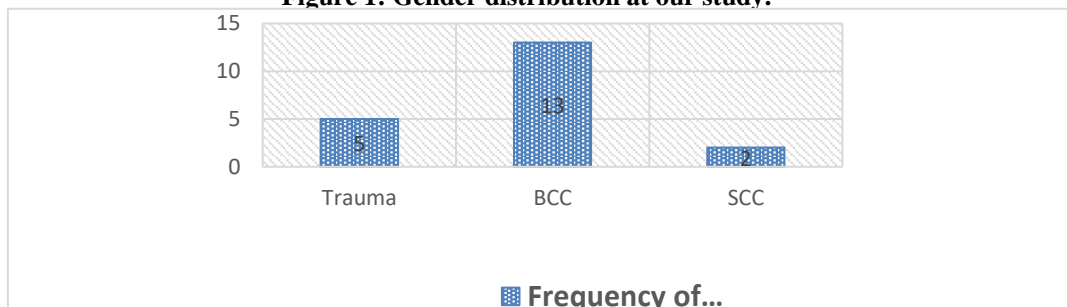
**Table 3: Summary of study outcome**

Patients' satisfaction		
	Frequency	Percent
Poor (0)	0	0
Accepted (1)	4	20
Good (2)	6	30
Very good (3)	0	0
Excellent (4)	10	50
<b>Deglutition</b>		

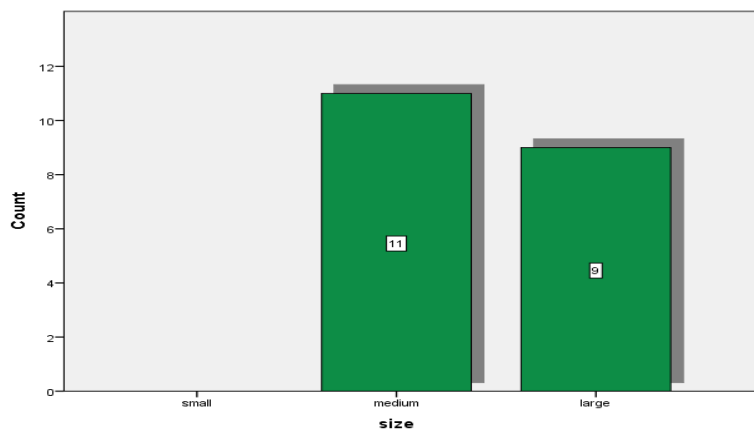
Patients' satisfaction		
Affected	4	20
Not affected	16	80
Verbal function		
Affected	4	20
Not affected	16	80
Complications		
No complications	14	70.0
Scar	1	5.0
central necrosis	1	5.0
small stoma plus a scar	4	20.0



**Figure 1: Gender distribution at our study.**



**Figure 2: Frequency of pathologies**



**Figure 3: Classification of defects.** Small defects are used to be closed primarily. In this figure, small defects were almost less than 2 cm<sup>2</sup> and can be closed almost primarily.

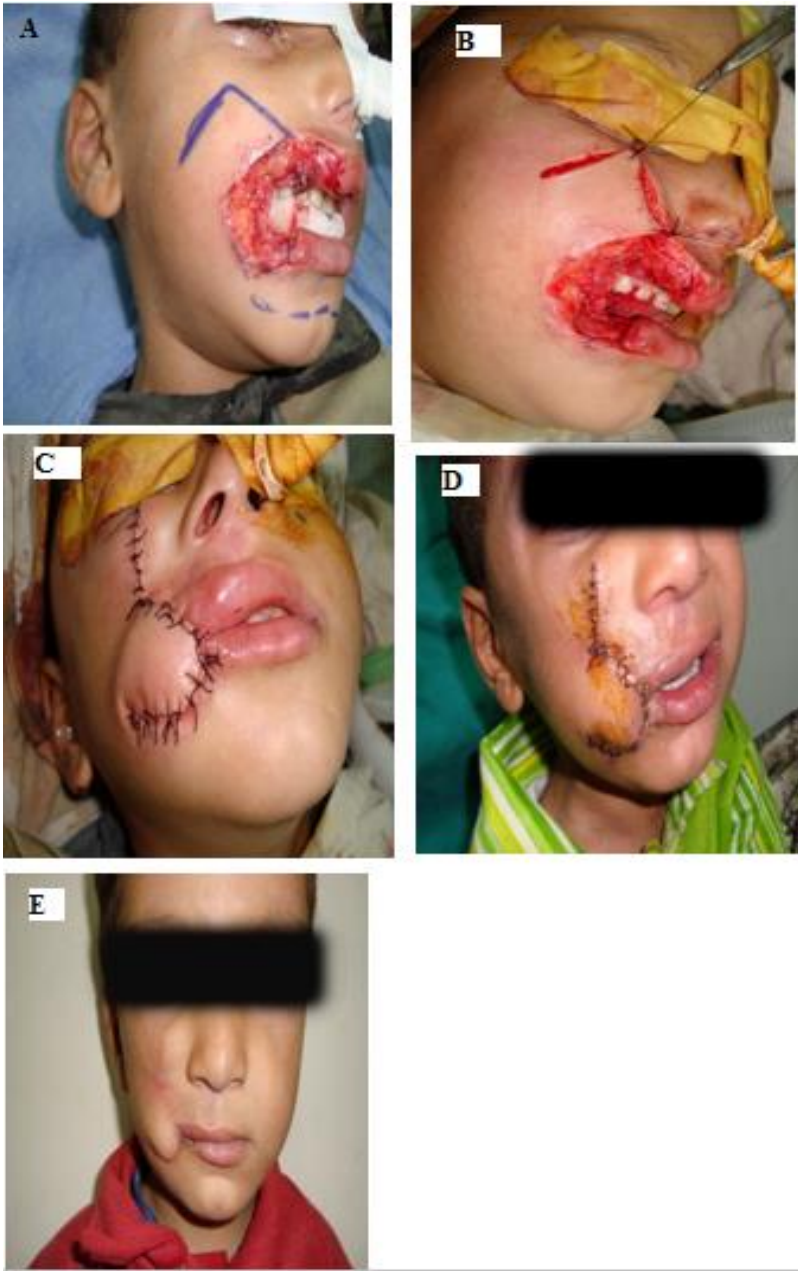
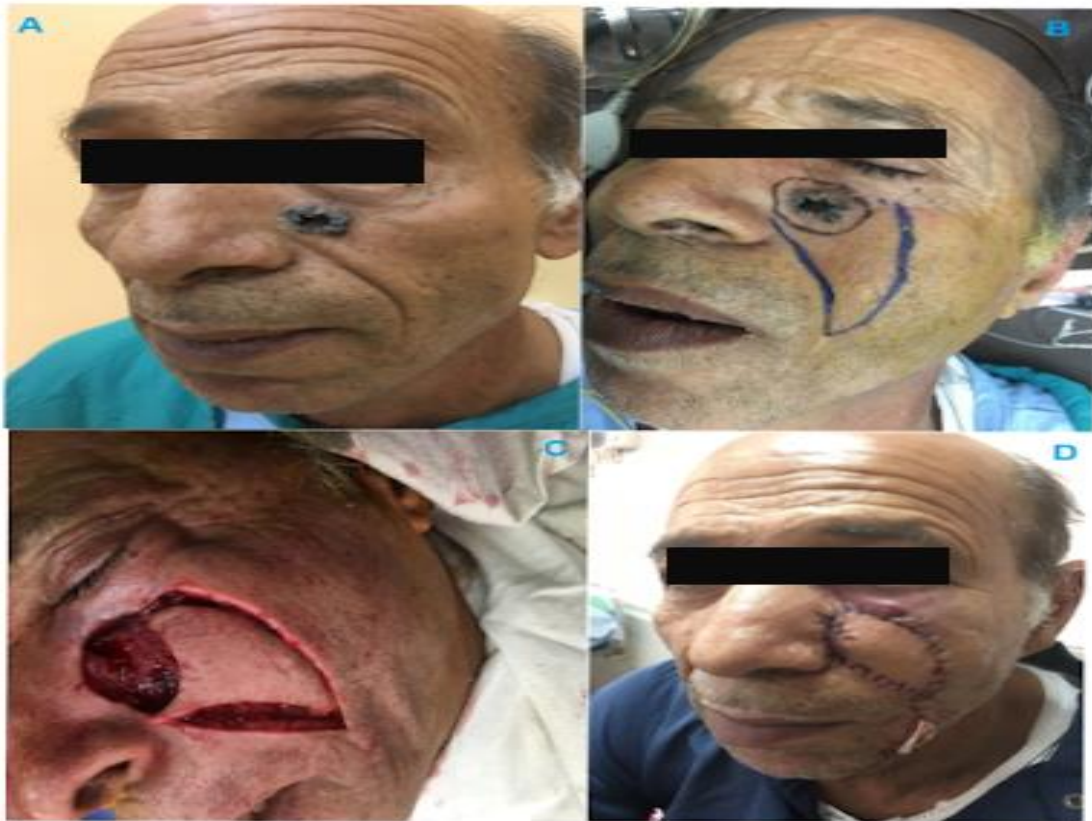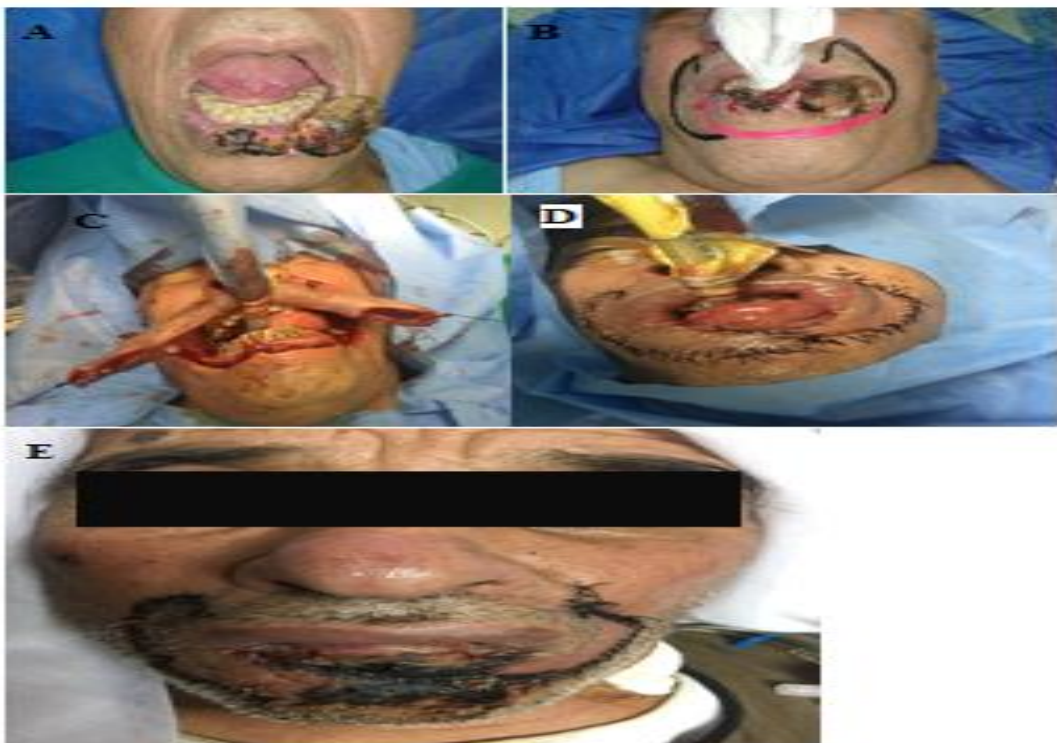


Figure 4: Flap types



**Figure 6:** A sixty-three years old male patient with left cheek ulceration (proved later Basal cell carcinoma). The flap used was nasolabial flap  
A skin lesion in left cheek B flap design draw, C lesion excision and flap elevation, D closure the defect by nasolabial flap



**Figure 7:** A seventy-six years old male patient presented with lower lip basal cell carcinoma. The flap used was a bilateral-Karapandzic flap.  
A, show the lesion in the lip. B, flap design. C, intraoperative elevation the flap. D, closure of the flap. E, 7-days postoperatively.

## DISCUSSION

This prospective study has been conducted in plastic surgery unit, Zagazig University Hospitals between December 2017 and June 2018. Twenty patients with defects in the mid and lower face either post-neoplastic or posttraumatic were included in the study. Age range of our patients was 10-77 years with a mean of  $45\pm 4.7$  years. Trauma patients represented a younger age group while post-neoplastic cases represented the older age group. Both sexes were included with no clear difference between males and females. Risk factors as DM and hypertension were presented in 6 of our patients (30%).

Flap success was recorded in 90% of our cases, only 2 cases showed infection and wound dehiscence, one of them was diabetic and the other was in young child with extensive facial laceration from animal bite. The fact that diabetic acts as a risk factor for infection and wound dehiscence was supported by the result of many studies. **Ducic and Attinger** found that associated comorbidities as diabetes have a negative impact on flap success and healing [10]. Regarding patient satisfaction, in the study we put the first priority during flap design in post-neoplastic cases for tumor free patients with free resection margins both in periphery and the depth [2,11–13].

This point was mentioned by **Yıldız and Selimen** who reported that this preoperative discussion makes the patient accept postoperative results as regards esthetic outcome [14]. Most of our post-neoplastic cases were satisfied about results of surgery and were accepting deformities later on. A finding which was supported by **Yıldız and Selimen** [14].

On the other hand, we found that, younger patients had a different response about postoperative results than elderly patients. They mainly put in mind the esthetic results of reconstruction [15–18]. **Pierre et al.**, had the same conclusion about impact of age on patient satisfaction and stated that younger patients were less satisfied than older even in post-neoplastic cases and more especially in posttraumatic patients [16].

Poor satisfaction was noticed in 20% of patients. Most of them had wide defects especially in lower lip involving more than 40% [19,20]. These cases showed defects in both phonation and deglutition. In this study, the main problem in these cases was related to defects in phonation rather than deglutition. **Bozec et al.** and **Pierre et al.** supported our findings and stated that speech was a remarkable factor as regards patient satisfaction after lower lip reconstruction as it remarkable affect quality of life [16,22].

## CONCLUSION

Meticulous selection of facial flap for every lesion is mandatory for gaining not only better results

aesthetically but to protect patient's self-image, self-esteem and prevention of associated depression.

## REFERENCES

1. **Summers BK, Siegle RJ.** Facial cutaneous reconstructive surgery: Facial flaps. *JAADM.* 1993;29(6):917-941. doi:10.1016/0190-9622(93)70271-T
2. **Shindo M.** Facial reanimation with microneurovascular free flaps. *OTOHNS.* 2000;11(2):147-149. doi:10.1016/S1043-1810(00)80031-7
3. **Wermker K, Kleinheinz J, Jung S, Dirksen D.** Soft tissue response and facial symmetry after orthognathic surgery. *JCMS.* 2014;42(6). doi:10.1016/j.jcms.2014.01.032
4. **Wei F, Jain V, Celik N, Chen H, Chuang DC-C, Lin C.** Have we found an ideal soft-tissue flap? An experience with 672 anterolateral thigh flaps. *PRS.* 2002;109(7):2219-2226; discussion 2227-30. doi:10.1097/00006534-200206000-00007
5. **Holmgren EP, Dierks EJ, Assael LA, Bell RB, Potter BE.** Facial soft tissue injuries as an aid to ordering a combination head and facial computed tomography in trauma patients. *JOMS.* 2005;63(5):651-654. doi:10.1016/j.joms.2004.10.009
6. **Zhou R, Wang C, Qian Y, Wang D.** Combined flaps based on the superficial temporal vascular system for reconstruction of facial defects. *JPRAS.* 2015;68(9):1235-1241. doi:10.1016/j.bjps.2015.04.022
7. **Kueckelhaus M, Fischer S, Lian CG, et al.** Utility of sentinel flaps in assessing facial allograft rejection. *PRSJ.* 2015;135(1):250-258. doi:10.1097/PRS.0000000000000797
8. **Braasch DC, Lam D, Oh ES.** Maxillofacial reconstruction with nasolabial and facial artery musculomucosal flaps. *OMSCNA.* 2014;26(3):327-333. doi:10.1016/j.coms.2014.05.003
9. **Lohn JWG, Penn JW, Norton J, Butler PEM.** The course and variation of the facial artery and vein: implications for facial transplantation and facial surgery. *APS.* 2011;67(2):184-188. doi:10.1097/SAP.0b013e31822484ae
10. **Ducic I, Attinger CE.** Foot and Ankle Reconstruction: Pedicled Muscle Flaps versus Free Flaps and the Role of Diabetes. *PRS.* 2011;128(1):173-180. doi:10.1097/PRS.0b013e3182173d3a
11. **Schmelzeisen R, Ptok M, Schonweiler R, Hacki T, Neukam FW.** [Reconstruction of speech and chewing function after extensive tumor resection in the area of the jaw and face]. *LRO.* 1996;75(4):231-238.

- doi:10.1055/s-2007-997567
12. **Ter Haar G, Buiks SC, Kirpensteijn J.** Cosmetic Reconstruction of a Nasal Plane and Rostral Nasal Skin Defect Using a Modified Nasal Rotation Flap in a Dog. *VS.* 2013;42(2):176-179. doi:10.1111/j.1532-950X.2012.01054.x
  13. **Vasconez HC, Buseman JL, Cunningham LL.** Management of facial soft tissue injuries in children. *JCFS.* 2011;22(4):1320-1326. doi:10.1097/SCS.0b013e31821c9377
  14. **Yıldız T, Selimen D.** The Impact of Facial Aesthetic and Reconstructive Surgeries on Patients' Quality of Life. *IJS.* 2015;77(December):831-836. doi:10.1007/s12262-013-1024-z
  15. **Pauloski BR, Rademaker AW, Logemann JA, Colangelo LA.** Speech and swallowing in irradiated and nonirradiated postsurgical oral cancer patients. *AAO-HNS.* 1998;118(5):616-624. doi:10.1177/019459989811800509
  16. **Pierre CS, Dassonville O, Chamorey E, et al.** Long-term quality of life and its predictive factors after oncologic surgery and microvascular reconstruction in patients with oral or oropharyngeal cancer. *EAORL.* 2014;271(4):801-807. doi:10.1007/s00405-013-2592-z
  17. **Rahpeyma A, Khajehahmadi S.** Combined Submental-tongue Flap for Reconstruction of Subtotal Traumatic Avulsion of Lower Lip: A Technical Note. *PRS-GO.* 2015;3(2):e302. doi:10.1097/GOX.0000000000000273
  18. **Rieger JM, Tang JAL, Wolfaardt J, Harris J, Seikaly H.** Comparison of speech and aesthetic outcomes in patients with maxillary reconstruction versus maxillary obturators after maxillectomy. *J. Otolaryngol. Head Neck Surg.* 2011;40(1):40-47.
  19. **Papadopoulos NA, Kovacs L, Krammer S, Herschbach P, Henrich G, Biemer E.** Quality of life following aesthetic plastic surgery: a prospective study. *J. Plast. Reconstr. Aesthet. Surg.* 2007;60(8):915-921. doi:10.1016/j.bjps.2007.01.071
  20. **Ozkan O, Coskunfirat OK, Ozkan O.** Midface reconstruction. *Semin. Plast. Surg.* 2010;24(2):181-187. doi:10.1055/s-0030-1255335
  21. **Bozec A, Poissonnet G, Chamorey E, et al.** Free-flap head and neck reconstruction and quality of life: a 2-year prospective study. *Laryngoscope.* 2008;118(5):874-880. doi:10.1097/MLG.0b013e3181644abd
  22. **Bozec A, Poissonnet G, Converset S, et al.** [Head and neck reconstructive surgery with free flaps and quality of life: a prospective study]. *Rev Laryngol Otol Rhinole.* 2007;128(1-2):11-18.

### How to cite

Nasser, M., El Sadek, A., Ali Ismaeel, A., Abdel Aal, M. Outcome of Local Flaps in Mid and Lower Face Reconstruction. *Zagazig University Medical Journal*, 2024; (113-120): -. doi: 10.21608/zumj.2021.56291.2088