



Manuscript ID ZUMJ-2109-2362 (R2)
DOI 10.21608/zumj.2021.98277.2362

ORIGINAL ARTICLE

Uterine Artery Doppler Ultrasound parameters for predicting the occurrence of persistent gestational trophoblastic neoplasia after evacuation of complete hydatidiform mole, a prospective comparative cohort study

Amr Abd-Almohsen Alnemr¹, Mohamed Ali Alabiad², Yasser S. Saraya¹

1. Department of Gynecology and Obstetrics, Zagazig University Faculty of Medicine, Zagazig, Egypt
2. Department of Pathology, Zagazig University Faculty of Medicine, Zagazig, Egypt

Corresponding Author:

Mohamed Ali Alabiad², Assistant
Professor of Pathology, Faculty of
Medicine, Zagazig University
Email;
maabyad@medicine.zu.edu.eg

Submit 2021-09-27
Date 15:48:31
Revise 2021-10-16
Date 14:56:54
Accept 2021-10-19
Date 12:52:52

ABSTRACT

background: Pelvic Doppler ultrasound is considered an essential diagnostic tool for evaluating uterine size and blood flow in patients with gestational trophoblastic neoplasia. However, it is still controversial whether evaluation of Doppler flow velocimetry (DFV) parameters of uterine artery is a good predictor of gestational trophoblastic neoplasia after complete hydatiform mole evacuation. Aim of the study was to compare uterine blood flow using Doppler ultrasound before and after evacuation of hydatiform mole between female patients with remissions and those with development of post-molar persistent gestational trophoblastic disease (PGTD) to detect accurate predictor factors of post-molar gestational trophoblastic malignancy.

Patients and methods: This is a prospective study included 80 females with complete hydatiform mole who underwent suction evacuation of uterine content, underwent uterine artery Doppler flow velocimetry (DFV) at admission and after vesicular mole evacuation.

We compare uterine blood flow using Doppler ultrasound before and after evacuation of hydatiform mole between female patients with remissions and those with development of post-molar persistent gestational trophoblastic disease (PGTD).

Results: 75% of included patients had spontaneous remission while remaining 20 (25%) patients had PGTD. Pre-evacuation RI and SD ratio (significantly lower in those who developed PGTD) and post-evacuation PI, (significantly higher in those who developed PGTD). PI was the Doppler parameter that was the most important associated factor with risk of PGTD.

Conclusions: uterine artery PI as the most important parameter which is related to higher risk of occurrence of PGTD after evacuation of complete hydatiform mole.

Keywords: complete hydatiform mole, Doppler ultrasound parameters, persistent gestational trophoblastic disease (PGTD)

INTRODUCTION

Progression of complete hydatidiform mole to gestational trophoblastic neoplasia was reported to occur in 9-20% of patients. Suction curettage is considered the standard method of complete hydatiform mole evacuation [1]. Identification of occurrence of postmolar malignancy was detected during follow-up by serial assessment of serum human chorionic gonadotropin (hCG). hCG rising or plateau

mostly points to progression to malignancy thus requiring chemotherapy.

Predicting liability to occurrence of post-molar malignancy mainly in patients with difficult continuous assessment of hCG is very important for adequate prompt management avoiding exposure to unnecessary chemotherapy [2].

There are many established predictive factors of post-molar malignancy as; patients age, size of ovaries, size of uterus, previous molar

pregnancy, serial assessment of hCG level [3], levels of vascular endothelial growth factor, TGF- beta 3 and HIF-1alpha [4].

Moreover Trans-vaginal ultrasound with power Doppler might be used as a predictive factor for delayed response and resistance to chemotherapy particularly low-risk trophoblastic diseases [5]. Pelvic Doppler ultrasound is considered an essential diagnostic tool for evaluating uterine size and blood flow in patients with gestational trophoblastic neoplasia [6].

Additionally changes in flow resistance might be able to assess appropriate chemotherapeutic regimen for management of gestational trophoblastic neoplasia in addition to evaluating chemotherapy response [7, 8]. Doppler ultrasound which is a noninvasive procedure for functional assessment of neo-vascularization, could assess patterns of highly abnormal flow in cases with invasive gestational trophoblastic neoplasia about two weeks post-evacuation before appearance of gross lesions and before marked rising hCG levels [7, 9].

However, it is still controversial whether evaluation of Doppler flow velocimetry (DFV) parameters of uterine artery was a good predictor of gestational trophoblastic neoplasia after complete hydatiform mole evacuation [10].

Aim of the study was to compare uterine blood flow using Doppler ultrasound before and after evacuation of hydatiform mole between female patients with remissions and those with development of post-molar persistent gestational trophoblastic disease (PGTD) to detect accurate predictor factors of post-molar gestational trophoblastic malignancy.

PATIENTS AND METHODS

This is a prospective study included 80 females with complete hydatiform mole who were admitted and managed in Gynecology and Obstetrics Department, Zagazig University, Faculty of Medicine in the period between March 2016 and April 2020.

Diagnosis of complete hydatiform mole was primarily based on ultrasound parameters confirmed by performing pre-evacuation B-

HCG titer, histopathological assessment after evacuation then by p57 immunohistochemistry [9].

Inclusion criteria

All female patients diagnosed with vesicular mole and were treated with suction evacuation of uterine content, underwent uterine artery Doppler flow velocimetry (DFV) at admission and after vesicular mole evacuation.

Exclusion criteria

We excluded; females with incomplete clinical data, patients who refused to be included in the study, female patients who have not undergone post-evacuation DFV or who were lost during the follow-up period after this procedure.

Our study was approved by the local institutional review board of Faculty of Medicine.

Written informed consents were obtained from included patients.

The study was done according to The Code of Ethics of the World Medical Association (Declaration of Helsinki) for studies involving humans.

After patient admission we collected clinical data as patients' age, number of previous pregnancies, previous history of abortion, parity, gestational age at diagnosis, size of the uterus, presence of ovarian theca lutein cysts which is associated with higher risk of malignant progression, and levels of pre-evacuation hCG [2].

We performed transabdominal sonography for pelvic global evaluation while we performed trans-vaginal imaging for detailed uterine, endometrial and adnexae evaluation.

We performed DFV of uterine arteries on both sides at admission as molar implantation site in the uterus was uncertain we repeated it 2 hours pre-evacuation to be sure of accuracy of its results and 4-6 weeks after evacuation.

We diagnosed occurrence of post-molar gestational trophoblastic neoplasia according to criteria standardized by the International Federation of Gynecology and Obstetrics [11] (1) Plateauing of levels of hCG of 4 values $\pm 10\%$ detected in 3-week duration (in days 1, 7, 14, and 21).

(2) Increasing levels of hCG more than 10% detected in 2-week duration (days 1, 7, and 14). Patients with PGTD were treated by a single dose of methotrexate 50mg/m² weekly [D1 D3 D5 D7] until normal hCG levels were reached. We diagnosed occurrence of disease remission after achieving undetectable levels of hCG for three consecutive weeks then after measuring its levels monthly for 1 year.

Statistical analyses

Statistical analysis of the data was performed by using software SPSS (Statistical Package for the Social Sciences) version 20. The relations between the Doppler indices obtained from the uterine arteries, between serum hCG titers and the mean Doppler indices calculated for each patient were compared using paired-t test, Pearson's correlation analysis, Kolmogorov-Smirnov (distribution-type) and Levene (homogeneity of variances) tests. The data obtained from the patients with PGTN and spontaneous remission was compared by the Mann-Whitney U test. ROC curve was used to determine cutoff of certain continuous variables for prediction of a health problem. The level statistical significance was set at $P < 0.05$. $p \leq 0.001$ was considered as statistically highly significant.

RESULTS

The study included 80 patients; sixty of them (75%) had spontaneous remission while remaining 20 (25%) patients had persistent gestational trophoblastic disease (PGTD) based on weekly assessment of hCG titers.

During the study period of 4 years, a total of 52 assessments were performed by assessment of serum hCG titers and Doppler ultrasonography. Figure 1

Mean age was 32 years while mean gestational age was 10.1 weeks. Gravidity ranged from 1 to 16 with median 8.5. Parity ranged from 0 to 8 with median 2. About 26% and 14% respectively had larger uterus for gestational age and theca lutein cyst. Table 1

There is statistically significant association between occurrence of PGTD and pre-

evacuation beta subunit of hCG (higher in those who developed PGTD). Table 2

Pre-evacuation RI and SD ratio (significantly lower in those who developed PGTD) and post-evacuation PI, (significantly lower in those who developed PGTD), RI and SD ratio (significantly lower in those who developed PGTD).

There is non-significant association between PGTD and pre-evacuation PI

Within group of patients who had spontaneous remission, there is significant increase in PI and SD after evacuation, and also there is significant change in RI.

In those with PGTD, there is significant decrease in PI while there is non-significant change in either RI or SD ratio after evacuation. Table 3

In multivariate regression analysis of factors significantly associated with PGTD among the studied patients, we showed that pre-evacuation beta subunit of hCG had neutral role (AOR=1) while higher post-evacuation PI decreases risk of PGTN (AOR=0.17, $p < 0.001$). Table 4; Figure 2

PI was the Doppler parameter that was the most important associated factor with risk of PGTN.

Pre-evacuation $PI \geq 1.25$ can predict PGTD among the studied patients with sensitivity 70%, specificity 56.7%.

Post-evacuation $PI \leq 2.65$ can predict PGTD among the studied patients with sensitivity 95%, specificity 60%.

Pre-evacuation $RI \leq 1$ can predict PGTD among the studied patients with sensitivity 75%, specificity 56.7%.

Pre-evacuation S/D ratio ≤ 6.5 can predict PGTD among the studied patients with sensitivity 80%, specificity 50%.

Post-evacuation S/D ratio ≤ 6.5 can predict PGTD among the studied patients with sensitivity 80%, specificity 51.7%.

Post-evacuation β -hCG ≥ 26926.5 can predict PGTD among the studied patients with sensitivity 80%, specificity 51.7%.

Table (1) Baseline data of the studied patients:

N=80	
Age:	
Mean \pm SD	32.0 \pm 7.21
Gravidity:	
Median (range)	6.5 (1 – 16)
Parity:	
Median (range)	2 (0 – 8)
Gestational age (week):	
Mean \pm SD	10.1 \pm 3.599
Uterus larger for GA:	
Absent	59 (73.8%)
Present	21 (26.2%)
Theca lutein cyst:	
Absent	69 (86.3%)
Present	11 (13.7%)
Fate:	
Remission	60 (75.0%)
PGTN	20 (25.0%)

Persistent gestational trophoblastic neoplasia (PGTN)

Table (2) Relation between occurrence of GTN and baseline data:

Doppler parameters	Outcome		p
	Spontaneous remission	GTN	
	N=60 (%)	N=20 (%)	
Age:			
Mean ± SD	32 ± 7.22	32 ± 7.35	>0.999 [¥]
Gestational age:			
Mean ± SD	10.1 ± 3.61	10.1 ± 3.67	>0.999 [¥]
Parity:			
Median (range)	2 (0 – 8)	2 (0 – 8)	0.857 [‡]
Gravidity:			
Median (range)	6.5 (1 – 16)	6.5 (1 – 16)	>0.999 [‡]
Pre-evacuation hCG:			
Median (range)	682 (382 – 2841719)	28421 (382 – 2842101)	0.017 ^{*‡}
Larger uterus for date			
	14 (23.3)	7 (35)	0.304 [∞]
Theca lutein cyst			
	7 (11.7)	4 (20)	0.454 [∞]

[¥]independent sample t test [‡]Mann Whitney test [∞]Chi square test *p<0.05 is statistically significant

Table (3) Relation between occurrence of PGTN and Doppler parameter pre and post evacuation:

Doppler parameters	Outcome		p [‡]
	Spontaneous remission	PGTN	
	Median (range)	Median (range)	
PI:			
Pre-evacuation	1.2 (0.6 – 3.6)	1.85 (0.8 – 3)	0.0075
Post-evacuation	3.1 (0.9 – 5.6)	1.4 (0.8 – 2.8)	<0.001**
p [¥]	<0.001**	0.042*	
RI:			
Pre-evacuation	1.1 (0.6 – 3)	0.85 (0.6 – 1.3)	0.008*
Post-evacuation	1.1 (0.6 – 2.9)	0.85 (0.6 – 1.3)	0.008*

Doppler parameters	Outcome		p [‡]
	Spontaneous remission	PGTN	
	Median (range)	Median (range)	
p [¥]	0.008*	>0.999	
SD:			
Pre-evacuation	6.5 (1 – 16.1)	4 (1 – 8)	0.01*
Post-evacuation	7 (1 – 19.7)	4 (1 – 8)	0.006*
p [¥]	<0.001**	>0.999	

¥Wilcoxon signed rank test ‡Mann Whitney test *p<0.05 is statistically significant **p≤0.001 is statistically highly significant

Pulsatility index (PI), Resistivity index (RI), Systolic/Diastolic ratio (S/D)

Table (4) Performance of Doppler parameter pre and postoperatively in prediction of GTN among the studied patients:

	AUC	Cutoff	Sensitivity	Specificity	PPV	NPV	Accuracy	p
Pre PI	0.633	≥1.25	70%	56.7%	35%	85%	60%	0.076
Post PI	0.84	≤2.65	95%	60%	44.2%	97.3%	68.8%	<0.001**
Pre RI	0.721	≤1	75%	56.7%	36.6%	87.2%	61.3%	0.003*
Post RI	0.706	≤1	75%	56.7%	36.6%	87.2%	61.3%	0.006*
Pre SD	0.693	≤6.5	80%	50%	34.8%	88.2%	57.5%	0.01*
Post SD	0.705	≤6.5	80%	51.7%	35.6%	88.6%	58.8%	0.006*
Pre β-hCG	0.678	≥26926.5	80%	51.7%	35.6%	88.6%	58.8%	0.018*

AUC area under curve PPV positive predictive value NPV negative predictive value *p<0.05 is statistically significant **p≤0.001 is statistically highly significant

Pulsatility index (PI), Resistivity index (RI), Systolic/Diastolic ratio (S/D)

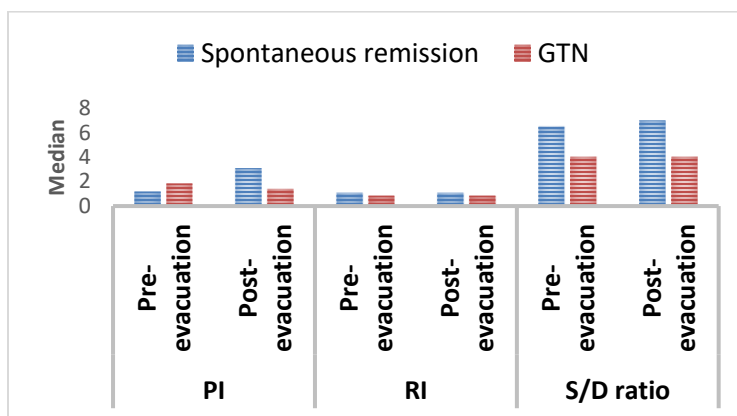


Figure (1) Multiple bar chart showing comparison between the studied groups regarding Doppler parameters before and after evacuation Pulsatility index (PI), Resistivity index (RI), Systolic/Diastolic ratio (S/D)

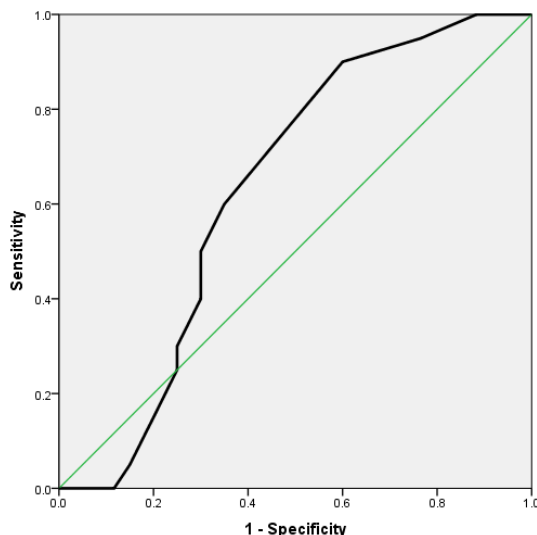


Figure (2) ROC curve showing performance of preoperative PI in prediction of GTN among the studied patients

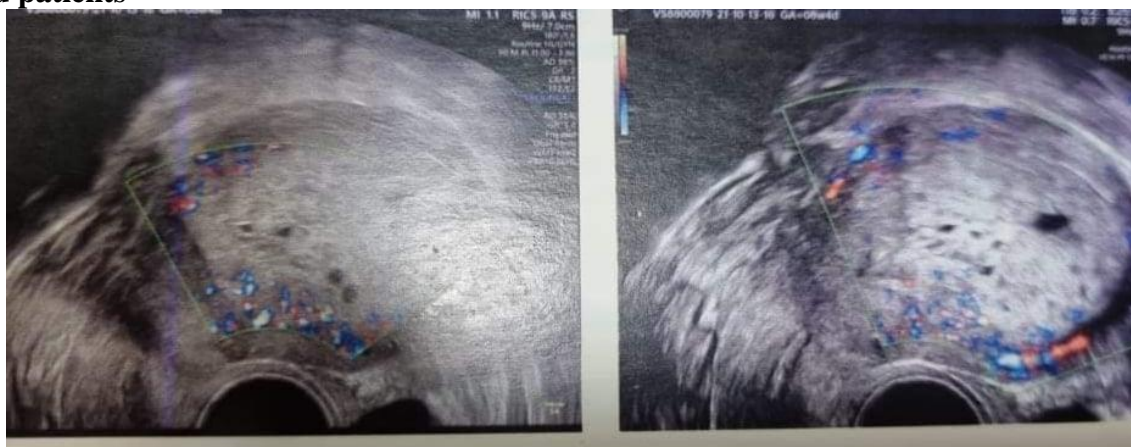

Figure (3) : Doppler ultrasound showed Complete mole with honeycomb appearance

DISCUSSION

Neoangiogenesis is an essential feature of oncogenesis, tumor growth, invasion, metastases and tumor progression [8, 12].

DFV is considered a noninvasive assessment procedure for neoangiogenesis in gestational trophoblastic diseases through assessing uterine arteries [2]. DFV is a better evaluation process than hCG measurements due to its role in detecting post-evacuation invasive gestational trophoblastic diseases before rising or plateau of levels [7, 13].

Our results showed that occurrence of gestational trophoblastic diseases after evacuation of complete hydatiform mole occurred in 25% of included cases; this rate is similar to rate detected by **Asmar et al.**, [2].

We showed that gestational age at diagnosis of the complete hydatiform mole has no association with development of post-molar gestational trophoblastic disease, as demonstrated by former studies [14, 15].

Compared to pre-evacuation measurements, the PI and S/D were increased in both uterine arteries after evacuation in patients with spontaneous remission.

While in those patients who developed PGTD, both the pre- and post-evacuation DFV measurements remained low. Similar results were reported by **Asmar et al.**, [2], **Sun et al 2015**[14], **Yalcin et al.** [13], **Malek et al.** [16].

Yalcin et al [13] and **Gungor et al.** [17] who showed similar findings to ours regarding uterine artery Doppler indices before evacuation of the mole and associations with occurrence of PGTD.

Different results were found by **Chan et al.** [18] that there were no differences in indices of uterine artery Doppler between patients with spontaneous remission and patients with development of post-molar persistent disease.

In our study, PI was the most important Doppler parameter which was strongly related to increasing risks of occurrence of post-complete hydatiform mole gestational trophoblastic neoplasia before and after mole evacuation,

these results were similar to results of previous studies [2, 7, 19].

These results collectively found that DFV measurements could detect patients with a higher risk of developing PGTD after complete hydatiform mole.

Former studies which assessed Doppler indices roles in predicting occurrence of trophoblastic neoplasia have provided conflicting results mostly due to little number of included patients and retrospective nature. Our present study included relatively large cohort of patients who were prospectively evaluated and showed that measurements of uterine DFV mainly pre- and post-molar evacuation PI, could be considered useful predictors of gestational trophoblastic neoplasia after complete hydatiform mole [8].

Doppler indices were found to identify patients at a high risk for development of post-evacuation gestational trophoblastic tumors particularly if levels of hCG levels are not helpful [13, 14, 16]. Moreover, Doppler ultrasound help in early diagnosis of gestational trophoblastic tumors as serial assessment of hCG levels could not detect them early in the first three weeks which delay their diagnosis, lead to an increased FIGO risk score and resistance to therapy [16]. Additionally, early detection of gestational trophoblastic tumors lead to reduction in their economic and social burden [20].

Summary and Conclusions:

In the present study we concluded that: 1) post-evacuation Doppler ultrasound parameters were significantly elevated in uterine arteries in both sides in patients with spontaneous remission, 2) our findings collectively validate Doppler ultrasound parameters particularly, uterine artery PI as the most important parameter which is related to higher risk of occurrence of persistent gestational trophoblastic disease (PGTD) after evacuation of complete hydatiform mole.

Recommendations

We recommend performing another large scale prospective study and including FIGO and WHO risk scoring in evaluation of predictive factors of PGTD.

REFERENCES

1. Qin J, Zhang S., Poon L., Pan Z., Luo j., Yu N et al. Doppler-based predictive model for methotrexate resistance in low-risk gestational trophoblastic neoplasia with myometrial invasion: prospective study of 147 patients. *Ultrasound Obstet Gynecol* 2021; 57: 829–839
2. Asmar F.,I Braga-Neto A, de Rezende-Filho J, Villas-Boas J, Charry R, Maestal I, Uterine artery Doppler flow velocimetry parameters for predicting gestational trophoblastic neoplasia after complete hydatidiform mole, a prospective cohort study *CLINICS* 2017;72(5):284-288.
3. Savage PM, Sita-Lumsden A, Dickson S, Iyer R, Everard J, Coleman R, et al. The relationship of maternal age to molar pregnancy incidence, risks for chemotherapy and subsequent pregnancy outcome. *J Obstet Gynaecol.* 2013;33(4):406-11.
4. Boufettal H, Feige JJ, Benharouga M, Aboussauira T, Nadifi S, Mahdaoui S, et al. Potential role of the angiogenic factor "EG-VEGF" in gestational trophoblastic diseases. *Pathol Biol (Paris).* 2013;61(5):178-83.
5. Cavoretto P, Gentile C, Mangili G, Garavaglia E, Valsecchi L, Spagnolo D, et al. Transvaginal ultrasound predicts delayed response to chemotherapy and drug resistance in stage I low-risk trophoblastic neoplasia. *Ultrasound Obstet Gynecol.* 2012; 40(1):99-105.uog.11097.
6. Seckl MJ, Sebire NJ, Berkowitz RS. Gestational trophoblastic disease. *Lancet.* 2010; 376(9742):717-29.
7. Oguz S, Sargin A, Aytan H, Kelekci S, Dumanli H. Doppler study of myometrium in invasive gestational trophoblastic disease. *Int J Gynecol Cancer.* 2004;14(5):972-9,
8. Agarwal R, Harding V, Short D, Fisher RA, Sebire NJ, Harvey R, et al. Uterine artery pulsatility index: a predictor of methotrexate resistance in gestational trophoblastic neoplasia. *Br J Cancer.* 2012;106(6):1089-94.
9. Maymon R, Schneider D, Shulman A, Bukowsky I, Weinraub Z. Serial color Doppler flow of uterine vasculature combined with serum beta-hCG measurements for improved monitoring of patients with gestational trophoblastic disease. A preliminary report. *Gynecol Obstet Invest.* 1996; 42(3):201-5.
10. Lin LH, Bernardes LS, Hase EA, Fushida K, Francisco RP. Is Doppler ultrasound useful for evaluating gestational trophoblastic disease? *Clinics.* 2015;70(12):810-5.
11. FIGO Oncology Committee. FIGO staging for gestational trophoblastic neoplasia 2000. *Int J Gynaecol Obstet.* 2002; 77(3):285-7.
12. Hanahan D, Weinberg RA. Hallmarks of cancer: the next generation. *Cell.* 2011; 144(5):646-74.
13. Yalcin OT, Ozalp SS, Tanir HM. Assessment of gestational trophoblastic disease by Doppler ultrasonography. *Eur J Obstet Gynecol Reprod Biol.* 2002;103(1):83-7,
14. Sun SY, Melamed A, Goldstein DP, Bernstein MR, Horowitz NS, Moron AF, et al. Changing presentation of complete hydatidiform mole at the New England Trophoblastic Disease Center over the past three decades: does early diagnosis alter risk for gestational trophoblastic neoplasia? *Gynecol Oncol.* 2015;138(1):46-9,
15. Lertkachonsuk A, Israngura N, Tangtrakul S, Thanappapras D, Charakorn C, Chittithaworn S. Complete hydatidiform mole Change in clinical profile over three decades. *J Reprod Med.* 2012; 57(11):470-4.
16. Malek M, Moradi B, Mousavi AS, Ahmadinejad N, Kazemi MA, Gity M. Complementary role of ultrasound in management of gestational trophoblastic disease. *Iran J Radiol.* 2015; 12(2):e13955.
17. Gungor T, Ekin M, Dumanli H, Gokmen O. Color Doppler ultrasonography in the earlier differentiation of benign molehydatidiforms from malignant gestational trophoblastic disease. *Acta Obstet Gynecol Scand.* 1998;77(8):860-2,
18. Chan FY, Pun TC, Chau MT, Lam C, Ngan HY, Wong RL. The role of Doppler sonography in assessment of malignant trophoblastic disease. *Eur J Obstet Gynecol Reprod Biol.* 1996;68(1-2):123-8.
19. Sita-Lumsden A, Medani H, Fisher R, Harvey R, Short D, Sebire N, et al. Uterine artery pulsatility index improves prediction of methotrexate resistance in women with gestational trophoblastic neoplasia with FIGO score 5-6. *BJOG.* 2013;120(8):1012-5,
20. Maestá I, Growdon WB, Goldstein DP, Bernstein MR, Horowitz NS, Rudge MV, et al. Prognostic factors associated with time to hCG remission in patients with low-risk postmolar gestational trophoblastic neoplasia. *Gynecol Oncol.* 2013;130(2):312-6.

To Cite

Alnemr, A., Alabiad, M., Saraya, Y. Uterine Artery Doppler Ultrasound parameters for predicting the occurrence of persistent gestational trophoblastic disease (PGTD) after evacuation of complete hydatidiform mole, a prospective comparative cohort study. *Zagazig University Medical Journal*, 2022; (106-114): -. doi: 10.21608/zumj.2021.98277.2362