



Original article

Evaluation of Laparoscopic Varicocelectomy in Adult Men

Ahmed H. Hussein¹, Ahmed M. Ghanem¹, Mohammed Faisal¹, Ahmed Abo Bakr^{1*}

Department of Surgery, Faculty of Medicine, Suez Canal University, 41522, Ismailia, Egypt

Corresponding author*:

Ahmed Abo Bakr

E-mail:

dr.ahmedabobaker@med.suez.edu.eg

Submit Date 2022-12-10

Accept Date 2022-12-15

Abstract

Background: Varicocele is an abnormal dilatation and tortuosity of the testicular veins. Blocking the reflux in the internal spermatic vein is the cornerstone treatment for varicocele. Treatment options include inguinal, subinguinal, retroperitoneal, scrotal, and laparoscopic approaches. Laparoscopic varicocele ligation results in lower morbidity, lower analgesic requirements, and more rapid rates of return to work as compared to the standard open surgical approach. The aim of the study was to evaluate the laparoscopic varicocelectomy (at 3 and 6 months postoperatively) as regards the intraoperative, postoperative laboratory, and radiological data.

Methods: This prospective study included 40 patients who underwent laparoscopic varicocelectomy procedure from March to November 2020.

Results: The study was conducted on 40 patients aged 17–36 years who underwent laparoscopic varicocelectomy. Clinically, only four patients were detected to be bilateral, although radiological assessment revealed 22 patients had bilateral affection. Clinically, the mean grade is 2.15 ± 0.67 for the left side and 0.35 ± 0.74 for the right side, which improved to 0.35 ± 0.57 on the former and 0.1 ± 0.44 on the latter at 6 months postoperatively. Based on ultrasound findings, 11 patients had bilateral affection. The mean grade is 2.25 ± 0.64 for the left side and 0.75 ± 0.78 for the right side, which improved to 0.35 ± 0.67 on the former and 0.35 ± 0.49 on the latter at 6 months postoperatively. In the semen analysis, the sperm count, motility, and abnormal forms significantly improved. The mean operative time and hospital stay were $26.15 + 5.03$ min and 1.15 ± 0.36 day, respectively.

Conclusions: Laparoscopic varicocelectomy is an effective treatment for varicocele. Significant symptom, sperm count, motility, and abnormal form improvements were observed during the postoperative follow-up. Therefore, laparoscopic varicocelectomy is recommended as more beneficial for patients.

Keywords: Varicocele; Laparoscope; Semen analysis; Duplex.



INTRODUCTION

Varicocele is an abnormal dilation of the pampiniform plexus, occurring in approximately 15% of male adolescents [1]. Varicocele is the most common correctable cause of male infertility that may result in testicular damage, whereas it may seemingly cause no ill

effects in other men [2]. Blocking the reflux in the internal spermatic vein while preserving the internal spermatic artery, lymphatics, and vas deferens is the cornerstone treatment for varicocele [3].

Several treatment options available include spermatic vein embolization and open surgical

ligation of the varix, through a retroperitoneal, inguinal, or subinguinal approach. Laparoscopic varicocelectomy has been proposed as an alternative surgical procedure to repair varicocele with reported benefits of better convalescence, minimal invasiveness, and less analgesic requirement postoperatively [4]. Laparoscopic surgery has the advantages of reduced morbidity, reduced analgesic requirements, and more rapid rate of return to work [5].

This technique is more advantageous than open surgery because it offers excellent visualization of the spermatic vessels. The number of veins to be ligated and arteries to be preserved is smaller, and their caliber is larger. Spermatic artery preservation is possible in 89–100% of patients [6]. The major advantage of the laparoscopic approach is that it allows a bilateral laparoscopic ligation through the same incisions, instead of two incisions required in an open surgical approach. However, the main disadvantages of laparoscopy are its higher cost and the need for multiple port placements, making it quite inappropriate in treating a unilateral varicocele [7].

METHODS

This is a prospective study conducted on 40 patients who underwent laparoscopic varicocelectomy from March to November 2020. Patients were considered appropriate candidates for this study if they were:

Willing to give consent and comply with the evaluation and treatment schedule, having a primary varicocele, no history of previous pelvic surgery and not having severe chronic illness, e.g., liver or renal insufficiency

Surgical procedure

Surgical procedures were performed under general anesthesia with the patient in supine position and surgeons standing on the right side of the patient, with the video monitor placed in front

of him, on the patient’s left side. The patient was placed in a modified Trendelenburg position.

Direct puncture laparoscopy was initiated by elevating the abdominal wall using two towel clips. A small incision was made in the umbilicus, and a Veress needle or port is placed in the abdominal cavity. The abdomen was inflated with a pressure-limited insufflator. Carbon dioxide (CO₂) gas was used, with pressures ranging from 14 to 15 mmHg. After a peritoneal insufflation, direct access to the abdomen was achieved using a 10 mm trocar (Fig. 1).

The laparoscope was inserted through the umbilical port, and peritoneal contents were inspected. Optimal insertion sites of the additional operative ports were then determined. Instrument port sites were selected in each lower quadrant so that instruments will easily reach the internal ring.

The posterior peritoneum was then grasped lateral to the testicular vessels and incised to form a window 2–3 cm from the deep inguinal ring (Fig. 2). The vascular structures were identified and isolated. Attempts were made to preserve the testicular artery and lymphatics (Fig. 3). Two clips were used on testicular veins (Fig. 4). In case of bilateral varicocele, the procedure is repeated on the opposite side.

Upon the completion of varix ligation, the ligation site was examined, and the patient was rotated to neutral position. The pelvis was inspected for any blood collection. With the patient returned to supine position, each sheath was removed under direct vision. Before removing the last ports, the insufflation valve was opened and the CO₂ gas was expelled from the peritoneal cavity. Wounds were closed using simple sutures.

Statistical analysis

Data were collected and entered to a spreadsheet. SPSS statistical package has been used for data analysis.

Table 1: Data of clinical findings

	Mean Grade (left)	Mean Grade (right)
Preoperative	2.15 ± 0.67	0.35 ± 0.74
Postoperative (3M)	0.25 ± 0.44	0
Postoperative (6M)	0.35 ± 0.57	0.1 ± 0.44

Table 2: Data of duplex findings

	Mean Grade (left)	Mean Grade (right)
Preoperative	2.25 ± 0.63	0.75 ± 0.78
Postoperative (3M)	0.25 ± 0.44	0.35 ± 0.49
Postoperative (6M)	0.35 ± 0.67	0.35 ± 0.49

Table 3: Comparison between preoperatively, 3 months postoperatively, and 6 months postoperatively according to the semen analysis results.

	Preoperative	Postoperative (3 months)	Postoperative (6 months)
Mean spermatic count in million/ml	29.08 ± 17.22	35.35 ± 16.138	39.3 ± 14.85
Mean motility(1st h) %	45 ± 9.73	49 ± 9.54	50.25 ± 6.97
Mean motility (2nd h) %	33.75 ± 8.717	34.5 ± 8.72	34.75 ± 8.95
Mean Motility(3rd h) %	18.55 ± 9.94	19 ± 8.67	18.3 ± 9.07
Abnormal forms %	34.9 ± 18.04	31.75 ± 15.66	29 ± 11.65

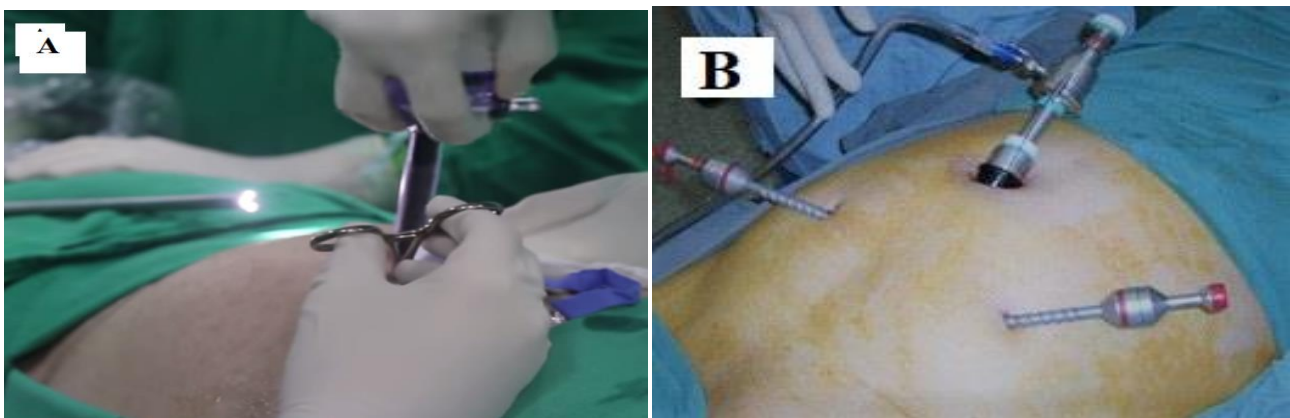


Fig. 1: A: port insertion, B: site of ports

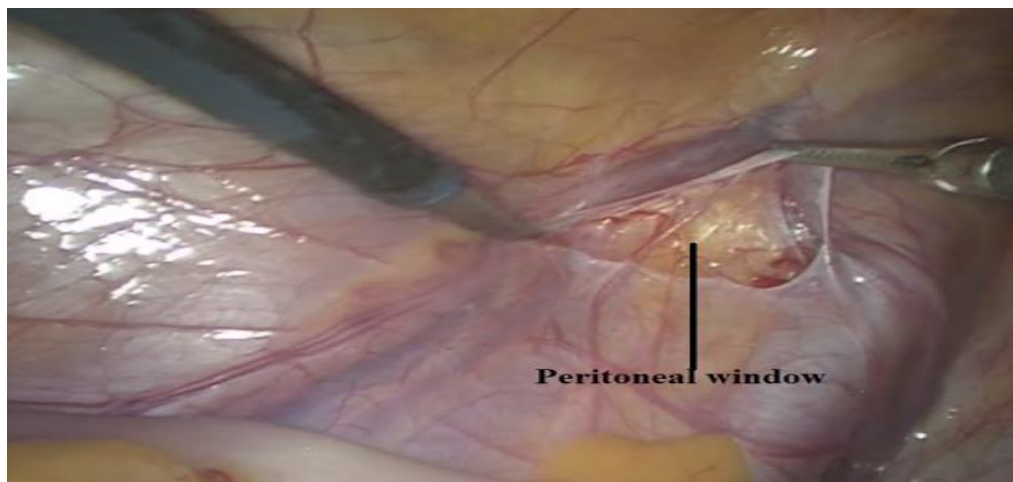


Fig. 2: Peritoneal window opening.

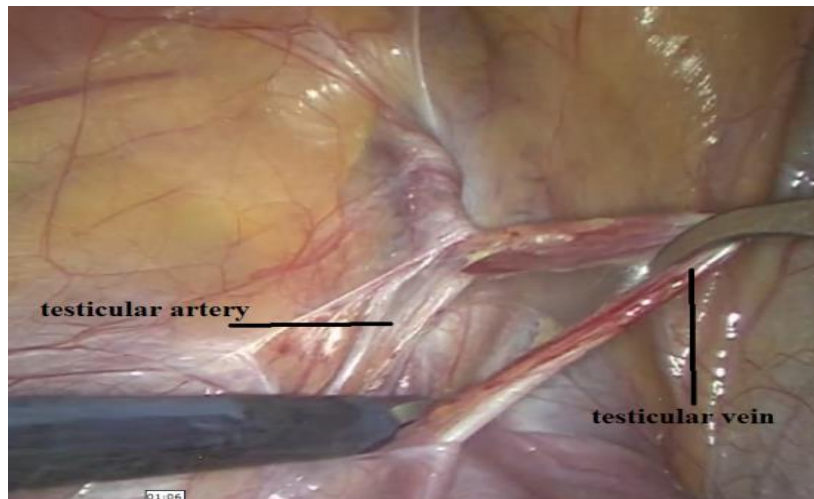


Fig. 3: Dissection and isolation of testicular vein.

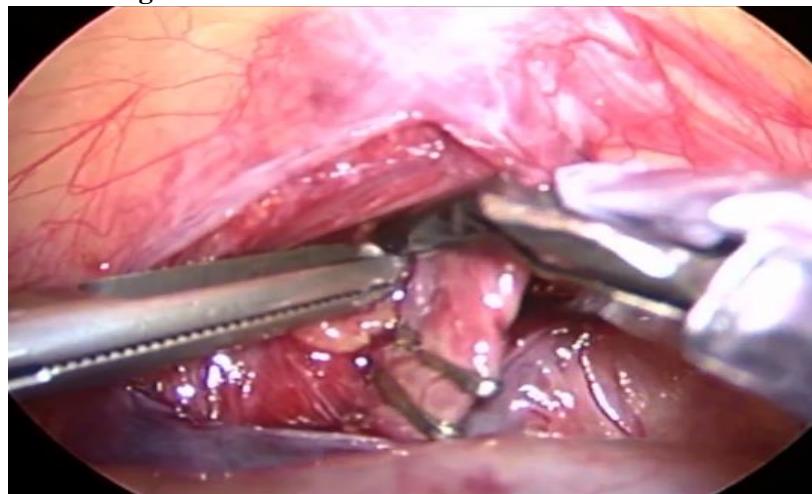


Fig. 4: Clips were applied on the testicular vein.

RESULTS

The study included 40 cases with varicocele aged 17–36 (mean, 25.95 ± 4.36) years (Table 1).

Clinically, 32 patients had left-sided affection, and only eight patients were detected to be bilaterally affected, although 22 patients were bilaterally affected based on the radiological assessment.

Pain was found as the most common presentation in the study group (50%), with the mean age of 26 ± 5.88 years, followed by swelling (25%) with mean age of 24.4 ± 2.3 and infertility (25%) with the mean age of 27.4 ± 1.14 .

Regarding the preoperative clinical grading, the mean grade is 2.15 ± 0.67 on the left side and 0.35 ± 0.74 on the right side, which improved to 0.35 ± 0.57 for the former and 0.1 ± 0.44 for the latter at 6 months postoperatively (Table 1).

Regarding the preoperative ultrasound, 22 patients were affected bilaterally. The mean grade is 2.25 ± 0.64 on the left side and 0.75 ± 0.78 on the right side, which improved to 0.35 ± 0.67 for the former and 0.35 ± 0.49 for latter at 6 months postoperatively (Table 2).

In the semen analysis, the sperm count improved in majority of patients, with the mean spermatoc count of $29.08 \pm 17.22 \times 10^6/\text{ml}$, which significantly increased to $39.3 \pm 14.85 \times 10^6/\text{ml}$ at 6 months postoperatively. The spermatoc motility improved postoperatively, but not statistically significant. Abnormal forms improved from $34.9 \pm 18.04\%$ to $29 \pm 11.65\%$ at 6 months postoperatively (Table 3).

The mean operative time and hospital stay were 26.15 ± 5.03 min and 1.15 ± 0.36 day, respectively.

One patient experienced a scrotal edema that improved after 10 days of conservative measures. During follow-up, none of the patients developed a postoperative hydrocele. Only two patients had recurrence of varicocele.

DISCUSSION

This study included 40 patients with primary varicocele aged 17–36 (mean, 25.95) years, which correspond to age of incidence primary varicocele (young adults). All patients underwent laparoscopic varicocelectomy.

In this study, all patients had left varicocele, and eight of them were clinically bilateral. However,

radiological measurements revealed additional 14 patients; most of them were grade I.

When comparing the pre- to postoperative status, only two patients showed residual affection, i.e., 10% recurrence rate.

Al-Kandari et al. (2007) reported improved the spermatic count in 67% of patients who underwent laparoscopic varicocelectomy. In this study, 38.3% of patients had improved the spermatic count [8]. The lower improvement percentage in this study can be explained by the fact that only 5 of 20 patients presented with infertility and low sperm count. The spermatic motility improved postoperatively, but not statistically significant. Regarding abnormal forms, the overall improvement was approximately 16.9%.

Furthermore, all procedures were completed satisfactorily, with no intraoperative complications. The mean operative time was 26.15 + 5.03 min. Podkamenev et al. (2002) reported that the operative time was 15 min for the laparoscopic varicocelectomy [9]. The more time taken in the laparoscopic group could be explained by 20% of those patients having bilateral varicocele and were subjected to bilateral intervention.

The hospital stay was 1.15 ± 0.36 day. Bebars et al. (2000) reported that the hospital stay was 1.3 day [10]. Majority of patients had moderate postoperative pain, which have been satisfactorily relieved with nonsteroidal anti-inflammatory drugs or paracetamol.

One patient experienced a scrotal edema that had improved after 10 days of conservative treatment. None of the patients in this study developed a postoperative hydrocele, which can be explained by easy identification of the testicular artery and lymphatics in majority of patients in this study.

Conclusions

Laparoscopic varicocelectomy is an effective treatment for varicocele, especially on spermatic count abnormal forms. Significant symptom, sperm count, motility, and abnormal form improvements were observed during the postoperative follow-up.

With laparoscopic varicocelectomy, identification and preservation of the testicular artery and lymphatics can easily be performed. Patients who underwent laparoscopic varicocelectomy had lower overall adverse events, shorter hospital stay, lower

morbidity, lower analgesic requirements, and more rapid rate of return to work than those who underwent the standard open surgical approach.

Conflict of interest: The authors declare that they have no conflict of interest.

REFERENCES

- 1.MF SFaB. In: Walsh PC RA, editor. Campbell's urology. 3. 8 ed: Elsevier; 2002. p. 3695-7.
- 2.Chiba K, Fujisawa M. Clinical outcomes of varicocele repair in infertile men: a review. *WJMH*. 2016;34(2):101-9.
- 3.Chiba K, Ramasamy R, Lamb DJ, Lipshultz LI. The varicocele: diagnostic dilemmas, therapeutic challenges and future perspectives. *Asian J. Androl*. 2016;18(2):276.
- 4.Kass E, Stork B, Steinert B. Varicocele in adolescence induces left and right testicular volume loss. *BJU international*. 2001;87(6):499-501.
- 5.Sangrasi AK, Leghari AA, Memon A, Talpur KA, Memon AI, Memon JM. Laparoscopic versus inguinal (Ivanissevich) varicocelectomy. *J Coll Physicians Surg Pak*. 2010;20(2):106-11.
- 6.Kachrilas S, Popov E, Bourdounis A, Akhter W, El Howairis M, Aghaways I, et al. Laparoscopic varicocelectomy in the management of chronic scrotal pain. *JSLs: Journal of the Society of Laparoendoscopic Surgeons*. 2014;18(3).
- 7.Sihoe J, Magsanoc N, Sreedhar B, Yeung C. Occasional Survey Laparoscopy in Paediatric Urology: Recent Advances. *HK J Paediatr (new series)*. 2004;9(1):65-73.
- 8.Al-Kandari AM, Shabaan H, Ibrahim HM, Elshebiny YH, Shokeir AA. Comparison of outcomes of different varicocelectomy techniques: open inguinal, laparoscopic, and subinguinal microscopic varicocelectomy: a randomized clinical trial. *Urology*. 2007;69(3):417-20.
- 9.Ribé N, Manasia P, Sàrquella J, Grimaldi S, Pomerol JM. Clinical follow-up after subinguinal varicocele ligation to treat pain. *Archivio Italiano di Urologia, Andrologia: Organo Ufficiale [di] Societa Italiana di Ecografia Urologica e Nefrologica*. 2002;74(2):51-3.
- 10.Bebars G, Zaki A, Dawood A, El-Gohary M. Laparoscopic versus open high ligation of the testicular veins for the treatment of varicocele. *JSLs*. 2000;4(3):209.

To Cite :

Hussein, A., Ghanem, A., Faisal, M., Abo Bakr, A. Evaluation of Laparoscopic Varicocelectomy in Adult Men. *Zagazig University Medical Journal*, 2024; (218-222): -. doi: 10.21608/zumj.2022.178922.2695