

## STUDY OF THE POSSIBLE HEPATOPROTECTIVE EFFECT OF PROPOLIS AGAINST THE HEPATOTOXIC EFFECT OF ATORVASTATIN IN ALBINO RATS

Ahmed A. Abdelsameea, Laila A. Mahgoub and Samar M. Abdel Raouf\*

Departments of Pharmacology and Pathology\* Faculty of Medicine-Zagazig University

### ABSTRACT

**Background:** Liver injuries induced by various hepatotoxins have been recognized as a major toxicological problem for years. 3-Hydroxy-3-methylglutaryl coenzyme A (HMG-CoA) reductase inhibitors (statins) are widely used drugs to reduce cholesterol levels and prevent coronary heart disease. One of the adverse effects of statins is affection of the liver functions with increased transaminases levels. Propolis is collected by honeybees from various plant sources. It was found to have hepatoprotective activity.

**Aim:** The present study evaluated the possible hepatoprotective effect of propolis against hepatotoxic effect of atorvastatin in albino rats.

**Methods:** Propolis in doses of 50 and 100mg/kg were administered one hour before atorvastatin in doses of 20 and 80mg/kg daily, orally for one month. Hepatoprotective effect of propolis was evaluated by measuring levels of ALT and AST in the serum and SOD and CAT in the liver homogenate. The histopathological studies were also studied to support the biochemical parameters.

**Results:** Atorvastatin in a dose of 20 and 80mg/kg produced dose-dependent, significant elevation of ALT, AST, SOD, CAT and hepatocyte degeneration. Administration of propolis 50 and 100mg/kg produced dose-dependent, significant reduction of the previous biochemical parameters and also prevented atorvastatin induced alterations in histoarchitecture of liver in a dose dependent manner.

**Conclusion:** Propolis protected the liver from the toxic effect of atorvastatin. The hepatoprotective effect of propolis may be due to its strong antioxidant activity.

### INTRODUCTION

**D**rug-induced liver injury (DILI) accounts for 9.5% of all suspected adverse drug reactions. Pre-clinical drug trials detect common DILI, but many are rare and detected only during post-marketing surveillance.<sup>1</sup> DILI is the most common reason for discontinuation of a new drug's development and withdrawal of an established one. DILI accounts for 14% of all cases of acute liver failure and is the leading cause for patients to be listed for super-urgent liver transplantation.<sup>2</sup>

It is well established that 3-hydroxy-3-methylglutaryl coenzyme A (HMG-CoA) reductase inhibitors (statins) reduce cholesterol levels and prevent coronary heart disease (CHD). The principal adverse effects of statins are myopathy, and marked increase in transaminases.<sup>3</sup> Patients may present with malaise, anorexia, and precipitous decreases in LDL.<sup>4</sup>

Propolis is a complex resinous hive product collected by bees from several plants, showing a very complex chemical composition. It has been used as a health drink and is extensively used in food to improve health and prevent diseases such as heart diseases and diabetes. It has also been used in the folk medicine due to its hepatoprotective activity.<sup>5</sup> In the last years, there is a renewed interest in the biological activities of propolis. It has therapeutic properties, such as antimicrobial, anti-inflammatory, antioxidant, immunomodulatory and antitumour activities, among others.<sup>6</sup> Propolis contains large amounts of antioxidative compounds, such as caffeic acid, ferulic acid and caffeic acid phenethyl ester.<sup>7</sup> For

this reason it attracts the attention of scientists to search for new therapeutic usage. Antioxidants play an important role in inhibiting and scavenging free radicals, thus providing protection to humans against infectious and degenerative diseases.<sup>8</sup>

The aim of the present study was to evaluate the possible hepatoprotective effect of propolis against hepatotoxic effect atorvastatin in albino rats.

### MATERIALS AND METHODS

**Drugs and chemicals:** Atorvastatin powder (EIPICO, Egypt), Ether anesthesia (El-Naser company, Egypt) propolis powder (Honey centers, Saint Kathreen, Egypt), Suspending agent [gum tragacanth] (El-Gomhoria company, Egypt). Propolis (50 and 100mg/kg) was administered to rats by preparing fresh suspension in distilled water and adding suspending agent [gum tragacanth] in a ratio of 4:1 respectively and shaken well before giving it orally by gastric gavage.<sup>9</sup>

Atorvastatin doses (20 and 80mg/kg) in 1ml distilled water orally by gastric gavage daily.<sup>10</sup>

**Animals:** Adult albino rats of either sex, weighing 190–220gm, were used in these experiments. The animals were kept in standard animal house. Food and water were available ad libitum.

All experimental protocols were approved by the ethics committee of Zagazig University.

**The experimental design:** 56 albino rats were divided into 7 groups, eight rats for each:

**Group I:** The rats were administered the suspending agent [gum tragacanth] for propolis

orally in a dose of 25mg/kg in 1ml distilled water daily for 1month.

**Group II:** Each rat of this group was administered atorvastatin orally, in a dose of 20mg/kg in 1ml distilled water daily for 1month.

**Group III:** Each rat of this group was administered propolis orally in a dose of 50mg/kg as 1ml suspension, then after one hour each rat was administered atorvastatin orally in a dose of 20mg/kg in 1ml distilled water daily for 1month.

**Group IV:** Each rat in this group was administered propolis orally, 100 mg /kg body weight then, after one hour atorvastatin was administered orally in a dose of 20mg/kg in 1ml distilled water daily for 1month.

**Group V:** Each rat was administered atorvastatin orally in a dose of 80mg/kg in 1ml distilled water daily for 1month.

**Group VI:** Each rat of this group was administered propolis orally in a dose of 50mg/kg as 1ml suspension, then after one hour each rat received atorvastatin orally in a dose of 80mg/kg in 1ml distilled water daily for 1month.

**Group VII:** Propolis in a dose of 100mg/kg as 1ml suspension was administered orally to each rat in this group, then after one hour atorvastatin was administered in a dose of 80mg/kg in 1ml distilled water daily for 1month.

#### **Biochemical studies:**

At the end of treatment period (30 days), blood samples were collected from retro bulbar venous plexus by very fine heparinized glass tubes. Blood samples were centrifuged (5000g; 15min at 4°C) and the clear supernatants were removed to estimate the serum alanine aminotransferase (ALT) and aspartate aminotransferase (AST). Blood samples were drawn by puncturing retro-orbital venous sinus, centrifuged and serum was isolated for estimation of transaminases AST & ALT.<sup>11</sup>

#### **Estimation of serum ALT and AST:**

**Principle:** Colorimetric determination of AST or ALT activities.

**Reagents:** AST Buffer substrate: Phosphate buffer pH 7.5(100 mmol/L), Aspartate (100 mmol/L),  $\alpha$ -Ketoglutarate (2 mmol/L). ALT Buffer substrate: Phosphate buffer pH 7.5 (100 mmol/L), Alanine (200 mmol/L),  $\alpha$ -Ketoglutarate (2 mmol/L). Color Reagent: 2, 4 dinitrophenylhydrazine 1 mmol/L. Standard pyruvate 2 mmol/L. Additional reagent: (available on request) Sodium hydroxide 0.4 N.

**Procedure:** Mix, Wait 5 min. Measure the absorbances at 505 nm (490 – 520 nm) against distilled water using cuvettes 1 cm light path. The

color is stable for one hour. Linearity for AST up to 150 units/ml and for ALT up to 120 units /ml.

**Calculation:** Calculate the number of units / ml of AST and ALT of sample using the standard curve.

#### **Liver Homogenates**

Prior to dissection, perfuse liver with a phosphate buffered saline solution, pH 7.4 containing 0.16 mg / ml heparin to remove any red blood cells and clots.

Homogenize the liver in 5 – 10 ml cold buffer (i.e., 50 mM potassium phosphate, pH 7.5. 1 mM EDTA) per gram liver. Centrifuge at 100,000 x g for 15 minutes at 4 °C. Remove the supernatant for assay and store on ice. If not assayed on the same day, freeze the sample at - 80°C. The sample will be stable for at least one month.

#### **Estimation of SOD and CAT activities in the liver homogenate:**

SOD activity was measured by the inhibition of pyrogallol autooxidation.<sup>12</sup> Briefly, 200  $\mu$ l of sample was mixed with 750  $\mu$ l cacodylic buffer (50 mM Tris-HCL, 50 mM cacodylic acid, 1 mM diethylenetriamine pentacetic acid, pH 8.2) and 200  $\mu$ l pyrogallol (2 mM). Absorbance was monitored at 420 nm for 3 min. one unit of SOD activity was defined as the amount of enzyme required to produce a 50% inhibition of pyrogallol auto-oxidation.

Catalase activity was measured by monitoring enzyme- catalyzed decomposition of H<sub>2</sub>O<sub>2</sub>. Briefly, a solution of H<sub>2</sub>O<sub>2</sub> was added to test tubes-containing samples, water blank, and an H<sub>2</sub>O<sub>2</sub> standard solution (Standard). After 3 min incubation, the enzymatic reaction was terminated by the addition of H<sub>2</sub>SO<sub>4</sub>. KMnO<sub>4</sub> (1.4 ml) was added to each tube, vortexes and absorbance recorded at 480 nm. One unit of catalase activity is defined as k/ (0.00693), where k= log (S<sub>0</sub>/S<sub>2</sub>) (2.3/t), S<sub>0</sub> is absorbance of standard minus absorbance of blank, S<sub>2</sub> is absorbance of standard minus absorbance of sample and t is time interval.<sup>13</sup>

**Histopathological study:** After the animals were anesthetized by ether, the liver of each animal was immediately dissected out to be processed for light microscope to show the toxic effect of atorvastatin and the protective effect of propolis and to compare with normal liver. Samples from the liver were fixed in 10% formalin, embedded in paraffin blocks and processed for preparation of sections. Sections were stained with hematoxylin and eosin.<sup>14</sup>

**Statistical analysis:** The obtained data were tabulated as means  $\pm$  SE. Comparison between different groups were made using one way analysis of variances (one-way ANOVA)

followed by post-hoc (least significant difference LSD) test. The differences were considered to be significant when  $p < 0.05$ . Statistical Package of Social Sciences (SPSS) computer software (version 14) was used to carry out the statistical analysis.

### RESULTS

#### Effect of oral administration of atorvastatin [20mg/kg] alone and in combination with propolis suspension in doses of [50 and 100mg/kg] for one month on the serum levels of AST& ALT and the activity of SOD& CAT in liver homogenates in albino rats.

In the control group where every rat was given distilled water 1ml with suspending agent (gum tragacanth 25mg/kg) orally daily for one month, the levels of AST, ALT were  $117 \pm 8.551$  and  $57 \pm 4.334$  IU/L respectively. Administration of atorvastatin in a dose of 20/kg for one month caused significant elevation of AST and ALT to  $152 \pm 9.242$  and  $68 \pm 4.573$  IU/L. Administration of propolis in a dose of 50mg/kg plus atorvastatin 20mg/kg for one month caused reduction of the elevated AST and ALT to  $125 \pm 7.313$  and  $59 \pm 3.962$  IU/L respectively which were

insignificant from the control levels but significantly reduced in relation to values of atorvastatin group. Oral administration of propolis in a dose of 100mg/kg plus atorvastatin 20mg/kg for one month caused reduction of the elevated AST and ALT to  $119 \pm 8.774$  and  $56 \pm 4.942$  IU/L respectively which were significantly reduced in relation to values of atorvastatin group but insignificant from the control levels.

In the liver homogenates, SOD and CAT activities in the control group were  $1.564 \pm 0.128$  and  $4.986 \pm 0.382$  which were significantly elevated after administration of atorvastatin in a dose of 20/kg for one month to  $1.889 \pm 0.147$  and  $5.502 \pm 0.476$  respectively. Administration of propolis in a dose of 50mg/kg plus atorvastatin 20mg/kg for one month caused significant reduction of the elevated SOD and CAT activities to  $1.402 \pm 0.098$  and  $5.012 \pm 0.364$ . With administration of propolis in a dose of 100mg/kg plus atorvastatin 20mg/kg for one month, SOD and CAT activities were significantly reduced to  $1.136 \pm 0.092$  and  $5.112 \pm 0.411$  (Table 1).

**Table (1):** Effect of oral administration of atorvastatin [20mg/kg] alone and in combination with propolis suspension in doses of [50 and 100mg/kg] for one month on the serum levels of AST& ALT and the activities of CAT& SOD in liver homogenates in albino rats.

	Control (n=8).	Atorvastatin (20mg/kg) (n=8)	Atorvastatin (20mg/kg) + Propolis (50mg/kg)(n=8)	Atorvastatin (20mg/kg) + Propolis (100mg/kg)(n=8)
AST	$117 \pm 8.551^A$	$152 \pm 9.242^B$	$125 \pm 7.313^A$	$119 \pm 8.774^A$
ALT	$57 \pm 4.334^A$	$68 \pm 4.573^B$	$59 \pm 3.962^A$	$56 \pm 4.942^A$
SOD	$1.654 \pm 0.128^A$	$1.889 \pm 0.147^B$	$1.402 \pm 0.098^C$	$1.136 \pm 0.092^D$
CAT	$4.986 \pm 0.382^A$	$5.502 \pm 0.476^B$	$5.012 \pm 0.364^A$	$5.112 \pm 0.411^A$

\* Means without common superscript capital letters are significantly different ( $P < 0.05$ ).

\*n = Number of rats

#### Effect of oral administration of atorvastatin [80mg/kg] alone and in combination with propolis suspension in doses of [50 and 100mg/kg] for one month on the serum levels of AST& ALT and the activities of CAT& SOD in liver homogenates in albino rats.

In control group where every rat was received distilled water 1ml with the suspending agent (gum tragacanth 5mg) orally daily for one month, the levels of AST, ALT and cholesterol were  $117 \pm 8.554$  and  $57 \pm 4.331$  IU/L respectively. Administration of atorvastatin in a dose of 80/kg for one month caused significant elevation of AST and ALT to  $247 \pm 15.575$  and  $118 \pm 9.141$  IU/L. Administration of propolis in a dose of 50mg/kg

plus atorvastatin 80mg/kg for one month caused significant reduction of the elevated AST and ALT to  $195 \pm 12.216$  and  $89 \pm 7.573$  IU/L respectively. Oral administration of propolis in a dose of 100mg/kg plus atorvastatin 80mg/kg for one month caused significant reduction of the elevated AST and ALT to  $129 \pm 7.526$  and  $63 \pm 4.343$  IU/L respectively and were insignificant from the control levels.

SOD and CAT activities in the liver homogenates in the control group were  $1.564 \pm 0.128$  and  $4.986 \pm 0.382$  which were significantly elevated after administration of atorvastatin in a dose of 80/kg for one month to  $1.978 \pm 0.126$  and  $5.813 \pm 0.409$  respectively. Administration of

propolis in a dose of 50mg/kg plus atorvastatin 20mg/kg for one month caused significant reduction of the elevated SOD and CAT activities to 1.863±0.112 and 5.007±0.365. With

administration of propolis in a dose of 100mg/kg plus atorvastatin 20mg/kg for one month, the SOD and CAT activities were significantly reduced to 1.581±0.095 and 4.889±0.365 (Table 2).

**Table (2):** Effect of oral administration of atorvastatin [80mg/kg] alone and in combination with propolis suspension in doses of [50 and 100mg/kg] for one month on the serum level of AST& ALT and the activities of CAT& SOD in liver homogenates in albino rats..

	Control (n=8).	Atorvastatin (80mg/kg) (n=8).	Atorvastatin (80mg/kg) + Propolis (50mg/kg)(n=8).	Atorvastatin (80mg/kg) + Propolis (100mg/kg)(n=8).
AST	117±8.554 <sup>A</sup>	247±15.575 <sup>B</sup>	195±12.216 <sup>C</sup>	129±7.526 <sup>A</sup>
ALT	57±4.331 <sup>A</sup>	118±9.141 <sup>B</sup>	89±7.573 <sup>C</sup>	63±4.343 <sup>A</sup>
SOD	1.654±0.128 <sup>A</sup>	1.978±0.126 <sup>B</sup>	1.863±0.112 <sup>B</sup>	1.581±0.095 <sup>A</sup>
CAT	4.986±0.382 <sup>A</sup>	5.813±0.409 <sup>B</sup>	5.007±0.365 <sup>A</sup>	4.889±0.365 <sup>A</sup>

\* Means without common superscript capital letters are significantly different (P<0.05).

\*n = Number of rats

**Histopathological finding:**

**Group I:** light microscopic examination of the liver revealed normal lobular architecture. The hepatic lobule was hexagonal in shape, consisting radically arranged cords of doublets of hepatocytes radiating from the central vein. These cords were separated by blood sinusoids and bile canaliculi were present in between the hepatocytes.

**Group II:** Rats given atorvastatin in a dose of 20mg/kg have minimal hepatocyte degeneration (hydrobic degeneration and fatty degeneration) were present. The parenchyma of the liver and the portal area were infiltrated by lymphocytes.

**Group III:** Rats given atorvastatin in a dose of 20mg/kg and propolis in a dose of 50mg/kg: the degenerative changes and swelling were lower in comparison to group II. Also the lymphocytic infiltrate were lower.

**Group IV:** When propolis dose increased to 100mg/kg, the changes recorded with atorvastatin 20mg/kg were reversed; the liver parenchyma was normal and the lymphocytic infiltrations in the portal area disappeared.

**Group V:** Damage to the liver was found after ingestion of atorvastatin (80mg/kg in 1ml distilled

water daily for 1month). Hepatocyte degeneration and swelling (hydrobic degeneration and ballooning) and fatty degeneration, hepatic parenchyma infiltration by lymphocytes (lytic and confluent necrosis) and the portal area also showed infiltration by mononuclear inflammatory cells with spillover of inflammation into the adjacent parenchyma (interface hepatitis).

**Group VI:** Rats given atorvastatin in a dose of 80mg/kg and propolis in a dose of 50mg/kg: hepatic lobular disruption is slightly improved, hepatocyte degeneration and swelling were lower in comparison to group V. Parenchyma and portal tract lymphocytic infiltration were lower than group V

**Group VII:** Rats given atorvastatin in a dose of 80mg/kg and propolis in a dose of 100mg/kg: improvements in hepatic histoarchitecture was found, hepatocyte degeneration and swelling were minimal. Parenchymal and portal tract lymphocytic infiltration were much lower than in group V and VI.

So propolis has the ability to reverse atorvastatin histological alterations and this effect is dose dependant.

**Table (3):** Effect of oral administration of atorvastatin [20mg/kg] alone and in combination

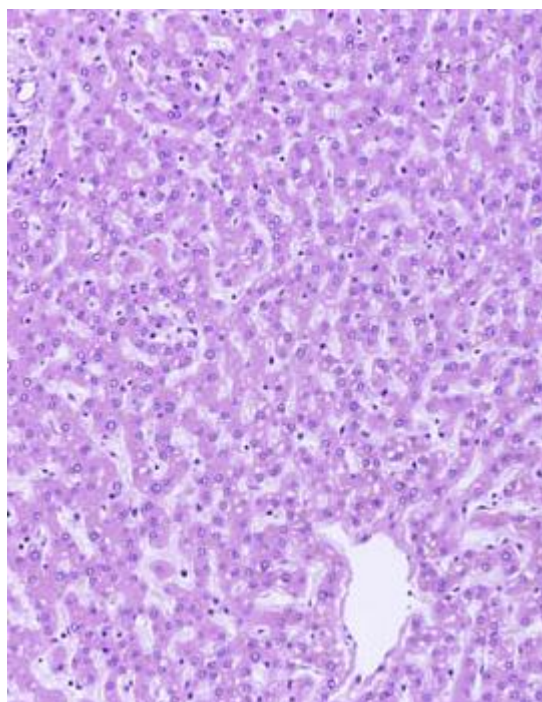
with propolis suspension in doses of [50 and 100mg/kg] for one month on liver histopathology in albino rats.

	Hepatic histoarchitecture	hepatocyte degeneration and swelling	Parenchymal and portal tract lymphocytic infiltration
Group I	Normal	-	-
Group II	Slightly disrupted	++	++
Group III	Moderately improved	+	+

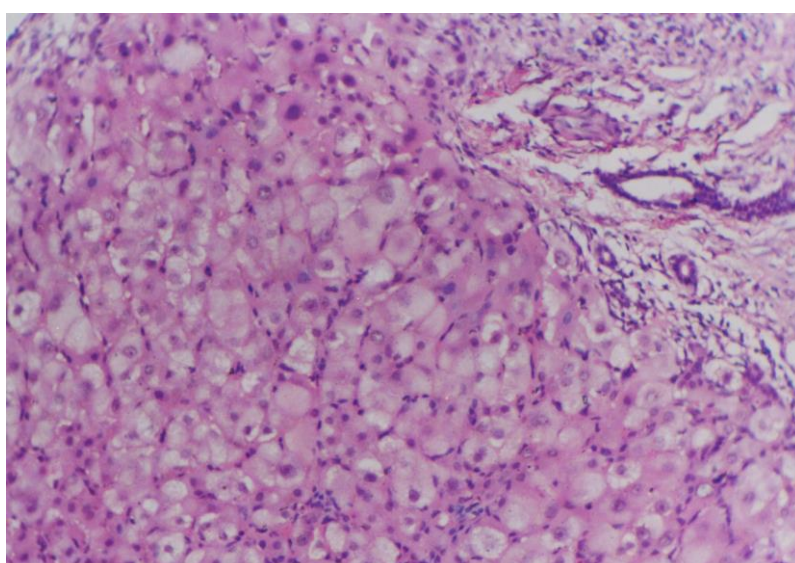


**Table (4):** Effect of oral administration of atorvastatin [80mg/kg] alone and in combination with propolis suspension in doses of [50 and 100mg/kg] for one month on liver histopathology in albino rats.

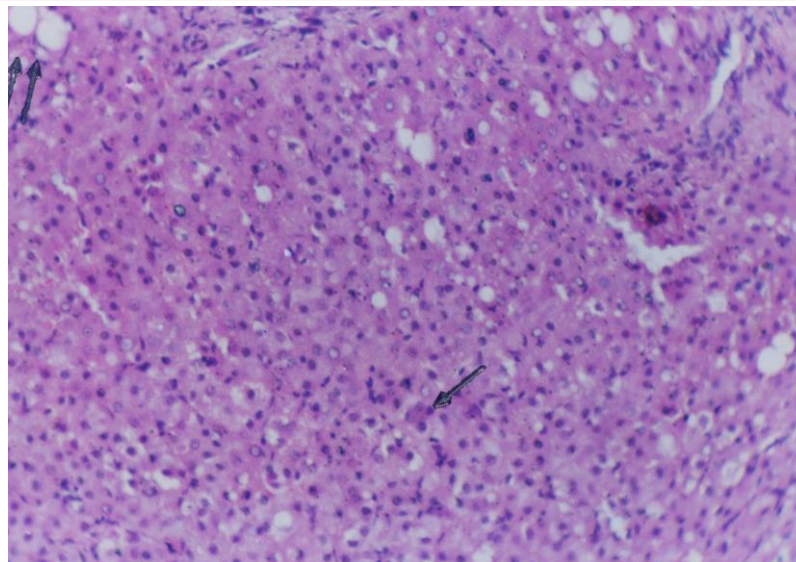
	Hepatic histoarcheticture	hepatocyte degeneration and swelling	Parenchymal and portal tract and lymphocytic infiltration
Group V	Disrupted	++++	++++
Group VI	Slightly improved	++	++
Group VII	Moderately improved	+	+



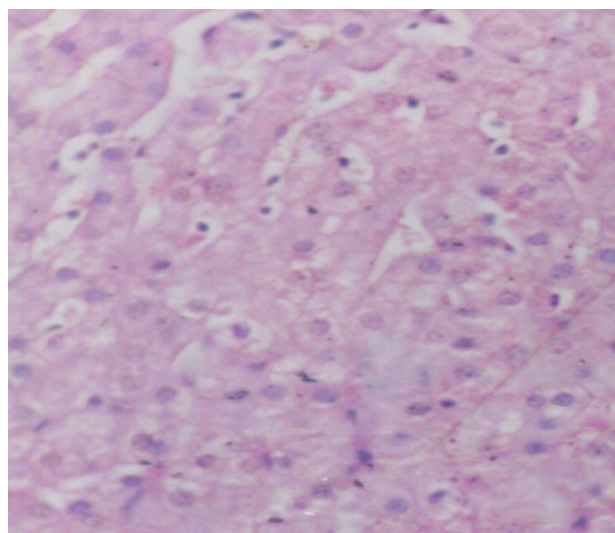
Microphotograph for group I: normal histoarcheticture



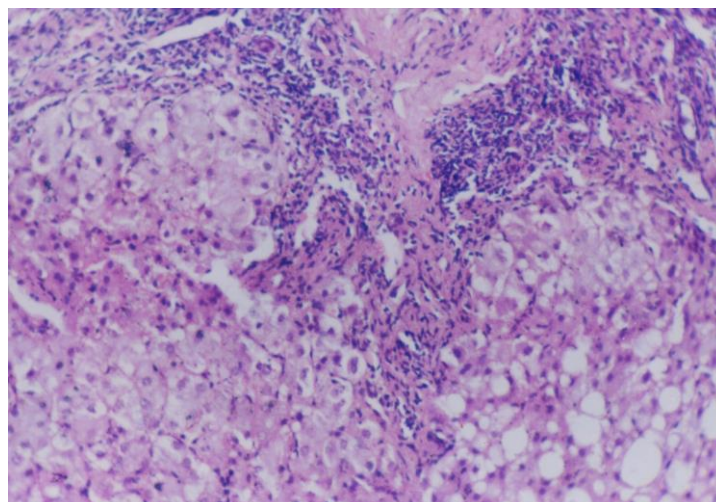
Microphotograph for group II: Mild interface activity, focal necrosis and lymphocytic infiltration of portal tract (H&EX600)



Microphotograph for group III: Mild lobular activity with spotty necrosis and focal steatosis. (H&EX300)

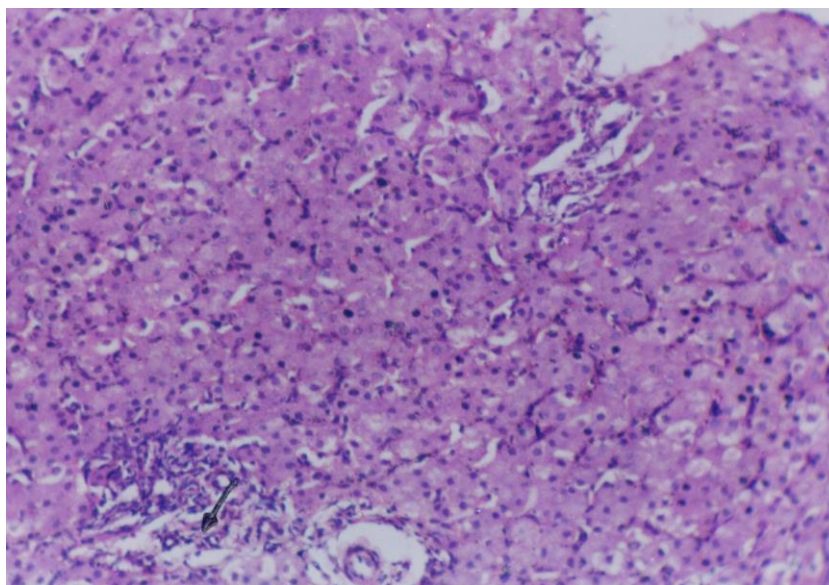


Microphotograph for group IV: Hepatic lobule is nearly normal. (H&EX600)

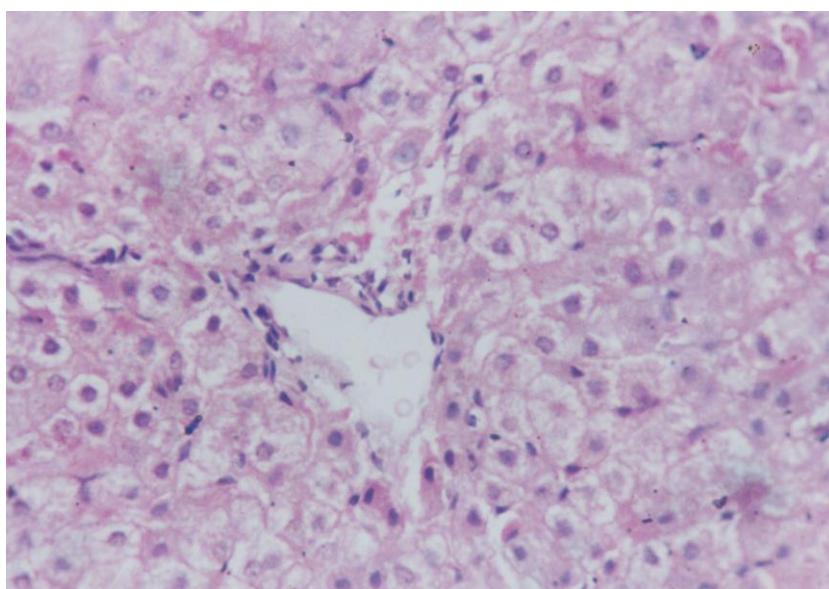


Microphotograph for group V: Severe interface activity with heavy lymphocytic infiltration periportal area and focal steatosis. (H&EX300)





Microphotograph for group VI: Focal lobular mononuclear infiltrate and portal inflammation. (H&EX300)



Microphotograph for group VII: Mild inflammatory reaction around the central vein (H&EX600)

### DISCUSSION

The results of the present study demonstrated that administration of atorvastatin in a dose of 20 and 80mg/kg daily for one month produced dose-dependent, significant elevation of serum AST and ALT levels. Our histopathological findings showed that atorvastatin in a dose of 20mg/kg have minimal hepatocyte degeneration while a dose of 80mg /kg caused marked hepatocyte degeneration. Also, atorvastatin in a dose of 20 and 80mg/kg daily for one month produced dose-dependent, significant elevation of SOD and CAT activities in the liver

homogenates which indicate the presence of oxidative stress. These findings cope with that obtained by **Malloy and Kane**<sup>4</sup> who reported that elevations of serum aminotransferase activity (up to three times normal) occur in some patients on statin therapy. Also, **Clarke and Mills**<sup>15</sup> concluded that, atorvastatin can cause significant acute hepatotoxicity. These serious hepatic reactions tend to occur in females, over 60 years, and persistent elevation in serum transaminases in this group should prompt early review of the need to continue with atorvastatin therapy.

In our results, groups treated with propolis 50 or 100mg/kg with atorvastatin 20 or 80mg/kg showed significant dose-dependent reduction of the serum levels of AST and ALT and the activities of SOD and CAT in the liver homogenate in relation those obtained in groups treated with atorvastatin alone. This means that propolis protected the liver from the oxidative stress occurred in groups treated with atorvastatin alone. Propolis treatment also reversed atorvastatin induced severe alterations in histoarchitecture of liver in a dose dependent manner.

These findings cope with **Arjun et al.**<sup>16</sup> who found that propolis has hepatoprotective activity on D-galactosamine: tumor necrosis factor- $\alpha$  - induced cell death in primary cultured mouse hepatocytes. Propolis contains more than 180 compounds including essential oils, flavinoids, phenolic acids and their esters.<sup>17</sup> Also, **El-Khatib et al.**<sup>18</sup> found that in isolated hepatocytes, aqueous propolis extract afforded protection against CCl<sub>4</sub>-induced injury as manifested by a decrease in the leakage of the cytosolic enzyme lactate dehydrogenase (LDH), decreased generation of lipid peroxide and maintenance of cellular reduced glutathione (GSH) content. In principle, similar findings were observed in liver homogenates. They reported that aqueous propolis extract has in vivo hepatoprotective potential which could be attributed at least in part to the maintenance of cellular GSH content. The latter effect seems to play an important role in conserving the integrity of biomembranes as it was associated with a decrease in lipid peroxidation and reduced leakage of cytosolic LDH.

Also **Bhadoria et al.**<sup>19</sup> demonstrated that propolis therapy produced duration-dependent protection, with maximal protection achieved at 24 h after CCl<sub>4</sub> exposure. They believed that propolis in its natural form has general pharmacologic value and marked hepatoprotective potential because of its composition of minerals, flavonoids, and phenolic compounds.

Several studies demonstrated that, activation of nuclear factor (NF) kappa B by tumor necrosis factor is completely blocked with caffeic acid phenethyl ester (CAPE), a component of propolis, in a dose dependant manner. CAPE also inhibited NF kappa B activation induced by other inflammatory agents including propol esters, ceramide, hydrogen peroxide and okadaic acid.<sup>20</sup>

**In conclusion**, propolis has a hepatoprotective effect against the hepatotoxicity induced by atorvastatin. This effect may be at least in part due

its powerful antioxidant effect. Further experimental and clinical studies are needed to confirm these results and its possible application for hepatic protection with patients on chronic statin therapy.

#### ACKNOWLEDGMENTS

The assistance of Dr. Rehab Karam, lecturer of biochemistry, faculty of medicine, Zagazig University is gratefully acknowledged.

#### REFERENCES

- 1- Bell LN, Chalasani N: Epidemiology of idiosyncratic drug-induced liver injury. *Semin Liver Dis*, 2009; 29: 337–347.
- 2- Adam D F, Alison B: Drug-induced liver injury. *Medicine*. 2011; 39, 9: 536–540.
- 3- Michael HD, Evan AS, Carlos AD, Donald B, Stuart RW, Robert HK: The Efficacy and Six-Week Tolerability of Simvastatin 80 and 160 mg/Day. *Am J Cardiol* 1997; 79:38–42.
- 4- Malloy JM, Kane JP: Agents used in hyperlipidemia. In: Katzung BG, Masters SB, Trevor AJ (Eds), *Basic & Clinical Pharmacology*. 12<sup>th</sup> ed., Mc Graw Hill Medical, New York, USA. 2012; 619-633.
- 5- Kolankaya D, Selmanoglu G, Sorkun K, Salih B: Protective effects of Turkish propolis on alcohol induced serum lipid changes and liver injury in male rats. *Food Chem*. 2002; 78: 213–217.
- 6- Yousef MI, Kamel KI, Hassan MS, El-Morsy AM: Protective role of propolis against reproductive toxicity of triphenyltin in male rabbits. *Food Chem. Toxicol*. 2010; 48: 1846–1852.
- 7- Kumazawa S, Ahn MR, Fujimoto T, Kato M: Radical-scavenging activity and phenolic constituents of propolis from different regions of Argentina. *Nat. Prod. Res.*, 2010; 24: 804–812.
- 8- Nader MA, El-Agamy DS, Suddek GM: Protective effects of propolis and thymoquinone on development of atherosclerosis in cholesterol-fed rabbits. *Arch. Pharm. Res*. 2010; 33: 637–643.
- 9- Shukla S, Bhadoria M, Jadon A: Effect of propolis extract on acute carbon tetrachloride induced hepatotoxicity. *Indian J. Exp. Biol*. 2004; 42(10): 993-7.
- 10- Garcia, GG, Miranda, HF, Noriega, V, Sierralta, F, Olavarría, L, Zepeda, RJ, Prieto, JC: Antinociception induced by atorvastatin in different pain models. *Pharmacology, Biochemistry and Behavior*. 2011; 100: 125–129
- 11- Reitman S, Frankel S: A colorimetric method for the determination of serum glutamic oxaloacetic and glutamic pyruvic transaminases. *Am. J. Clin. Pathol*. 1957; 28, 56–63
- 12- Marklund S, Marklund G: Involvement of the superoxide anion radical in the autooxidation of pyrogallol and a convenient assay for superoxide dismutase. *Eur J Biochem*. 1974; 47: 469-474.
- 13- Abei C: Catalase. In: Bergmeyer, HD (ed), *Methods of Enzymatic analysis*. Academic press, New York, Ny. 1974; 631-384.



- 14- Kiernan J: Histological and histochemical methods. In: Theory and Practice of histological techniques. 3<sup>rd</sup>ed. University of Western Ontario, London Ontario, Canada. 2001; 100-131.
- 15- Clarke AT, Mills PR: Brief Clinical Observation of Atorvastatin. Pharmacology, Biochemistry and Behavior. 2006; 100, 125–129.
- 16- Arjun HB, Yasuhiro TI, Ketut A, Katsumichi M, Dejair M, Alfredo AG, Shigetoshi K: Cytotoxic, hepatoprotective and free radical scavenging effects of propolis from Brazil, Peru, the Netherlands and China. Journal of Ethnopharmacology. 2000; 72: 239–246
- 17- Banskota AH, Tezuka Y, Prasain JK, Matsushige K, Saiki I, Kadota S Chemical constituents of Brazilian propolis and their cytotoxic activity. Journal of Natural Products. 1998; 61: 896–900.
- 18- El-Khatib AS, Agha AM, Mahran LG, Khayyal MT: Prophylactic effect of aqueous propolis extract against acute experimental hepatotoxicity in vivo. Z Naturforsch C. 2002; 57(3-4):379-85.
- 19- Bhadauria M, Nirala SK, Shukla S: Duration-dependent hepatoprotective effects of propolis extract against carbon tetrachloride-induced acute liver damage in rats. Adv Ther. 2007; 24(5):1136-45.
- 20- Seo KW, Park M, Song YJ, Kim S, Yoon KR: The protective effect of propolis on hepatic injury and its mechanism. Phytother. Res. 2003; 17(3): 250-253.