



Manuscript ID ZUMJ-1907-1350 (R5)  
DOI 10.21608/zumj.2019.14778.1350

**ORIGINAL ARTICLE**

## Clinical and pathological characteristics of breast giant fibro adenoma among young females

Alaa Mohamed Khalil<sup>1</sup>, Ramdan Mahmoud Mohamed<sup>2</sup>, Loay.M Gertallah<sup>3</sup>, Momen Abd El Hakeim Ayad<sup>4</sup>

<sup>1,2,3</sup>Department of General Surgery, Faculty of Medicine, Zagazig University, Egypt

<sup>4</sup>Alahrar Teaching Hospital, Department of General Surgery, Faculty of Medicine, Zagazig University, Egypt

### Corresponding author:

**Name:** Momen Abd El Hakeim Ayad Youssif

Alahrar Teaching Hospital,  
Department of General Surgery,  
Faculty of Medicine, Zagazig  
University, Egypt

**Email:**  
[ma.ayad@medicine.zu.edu.eg](mailto:ma.ayad@medicine.zu.edu.eg)

**Submit Date** 2019-07-21

**Revise Date** 2019-10-14

**Accept Date** 2019-10-18

### ABSTRACT

**Background:** Fibroadenoma is the most common breast tumor in adolescent and young women. Incidence of benign breast lesions is common in the second decade reaching its peak at fourth and fifth decade of life. These lesions usually arise in the fully developed breast between the ages of 15 and 30 years, although occasionally they occur in much older women. They arise from hyperplasia of a single lobule and usually grow up more than 5 cm in size and called giant fibroadenoma. The aim of the study is to determine clinicopathological features of giant breast fibroadenoma in females aged below 40 years in General Surgery Department, Zagazig University.

**Methods:** The study was carried out at General Surgery Department, Zagazig University Hospitals. The study included 30 female patients in the period between January 2019 and July 2019 presented with breast mass proved to be Giant fibroadenoma by breast ultrasonography and mammography.

**Results:** In our study we find out that clinical examination of breast giant fibroadenoma among the studied group has sensitivity of 88.9%, specificity of 66.7%. So histopathological examination after excisional biopsy is needed for more confirmation.

**Conclusions:** The sensitivity of clinical diagnosis of giant fibroadenoma in female patients  $\leq 30$  years in our study is good, but the specificity is low.

**Keywords:** Giant breast fibroadenoma, clinical picture, histopathological features

### INTRODUCTION

Giant fibroadenoma is a rare variant of fibroadenoma accounting for 0.5-2 per cent of all cases of fibroadenomas and is characterized by its larger size and rapid growth (size larger than 5 cm and weight may reach 500 grams). [1].

Giant fibroadenomas are identified by enormous and rapid increase in the size of a rubbery, mobile and non-tender mass. [2].

Fibroadenoma is the commonest benign breast tumor among young females. It is characterized histologically by being a

biphasic tumor with epithelial and stromal components. [3].

Fibroadenomas can occur at any age but are frequently discovered in young females between 20 and 30 years and has low incidence after the 4th decade of life. [4].

The exact etiology of fibroadenoma is still mysterious yet but it is suspicious that high estrogen levels and increased estrogen receptor sensitivity can cause these massive growth changes. [5].

Giant fibroadenomas are preferred to be treated surgically due to patient discomfort, massive growth and aesthetic concerns. [6].

It is important to distinguish giant fibroadenoma from phyllodes tumor because they have different management approaches.[7].

### **AIM OF THE WORK**

The aim of the study is to determine clinicopathological features of giant breast fibroadenoma in females aged below 40 years in General Surgery Department, Zagazig University.

### **PATIENTS AND METHODS**

The study was approved by the Ethical committee of the Faculty of Medicine, Zagazig University, Written informed consent was obtained from all participants. The work has been carried out in accordance with The Code of Ethics of the World Medical Association (Declaration of Helsinki) for studies involving humans. This prospective randomized study included a total of 30 female patients in the period between January 2019 and July 2019 presented with breast mass proved to be Giant fibroadenoma by breast ultrasonography and mammography.

#### **Inclusion criteria:**

All female patients aged  $\leq 40$  years old attended the outpatient clinic of Zagazig University Hospitals with breast lump in one side or both sides proved to be giant fibroadenoma by breast ultrasonography and mammography.

#### **Exclusion criteria:**

Female patients aged  $> 40$  years, Female patients with breast mass less than 5 cm and those who refused the study.

#### **Surgical technique**

After completing all investigations and from clinical examination and radiological finding all cases suspected to have giant fibroadenoma were prepared for excisional biopsy

Procedure:

After good control of any medical disease(s) associated with the condition, With induction of anesthesia, 1 gm of 3rd generation cephalosporin was given as prophylactic antibiotic.

Make an incision depending upon the location of the fibro adenoma, Make either a peri-areolar, sub-mammary or a lateral incision as preferred, If excision biopsy is indicated,

prefer a peri-areolar incision which results in the best cosmetic outcome, Move the fibroadenoma to the site of the nipple-areola complex using your non-dominant hand, With your dominant hand make a peri-areolar or inframammary

incision directly over the fibroadenoma and excise the lesion through this incision, Excise the fibroadenoma using sharp dissection staying close to the edge of the lesion, After removing the fibroadenoma pay meticulous attention to hemostasis using electrocautery, Subcutaneous drain was inserted and finally we Irrigate the wound then approximate the skin edges with subcuticular stitch.

The sepeciments labelled as breast excisional biopsy and sent for histopathological examination.

Post-operatively all patients were submitted to careful follow up by:

patients were encouraged for early mobilization from bed after 6 hours and started oral intake, post-operative analgesia was given in the form of diclofenac sodium 75mg IM every 12 hours, follow up of any post-operative complications such as wound infection, seroma, hematoma and numbness along the inner aspect of the arm, patients were advised for outpatient clinic visit with the report of histopathological examination, the sutures of the wound were removed from days 14, careful examination of the scar of the breast during the follow up period up to six months for any possible recurrence and patients encouraged for periodic self-examination for early detection of any new masses.

### **RESULTS**

All data were collected then statistically analyzed and tabulated. All statistical analysis was done using (SPSS) version 17

The data are presented as frequency and relative percentages and the differences between groups are calculated using chi-square test and fisher exact test was recommended when expected cell is less than 5.

One sample chi-square test was also used (probability (P) is considered significant, when P is less than 0.05).

Table(1) shows that the age of the studied participants ranged between 16 and 29 years with mean age of 24 years and the mean size of mass was 7.56 cm, table(2) shows that 66.7% of the studied women had fibroadenoma, 10% had fibro-adenosis and 16.7% needed further investigations and table(3) shows that 60% of the studied women had fibro-adenoma, 10% had duct ectasia and 10% had lipoma by histopathological examination.

Figure(1) shows Section in pericanalicular fibroadenoma which reveals

Proliferated ducts rounded or oval , patent lumen and lined by two layers of cells , outer

flattened and inner cubical,figure(2) shows Ultrasound of breast with giant fibroadenoma, figure(3) shows Mamogram of breast reveals well defined oval shaped lesion ( fibroadenoma), and finally figure(4) shows Gross picture of fibroadenoma after excision.

In our study we find out that clinical examination of breast giant fibroadenoma among the studied group has sensitivity of 88.9%, specificity of 66.7%.So histopathological examination after excisional biopsy is needed for more confirmation.

**Table (1): Socio-demographic data of the studied group:**

Variable	Studied group (n=30)	
	No	%
<b>Age:</b>		
Mean $\pm$ SD	23.8 $\pm$ 3.67	
Range	16 -29	
<b>Size of mass:</b>		
Mean $\pm$ SD	7.56 $\pm$ 3.67	
Range	5 – 10	
<b>Marital status:</b>		
Married:	18	60
Single:	12	40

**Table (2): Clinical diagnosis among the studied group:**

Variable	Studied group (n=30)	
	No	%
<b>Clinical diagnosis:</b>		
Cyst:	1	3.3
Duct ectasia:	1	3.3
Fibro-adenoma:	20	66.7
Fibro-adenosis:	3	10
Need further investigations:	5	16.7

**Table (3): Histopathological diagnosis among the studied group:**

Variable	Studied group (n=30)	
	No	%
<b>Histopathology:</b>		
Chronic abscess:	2	6.7
Duct ectasia:	3	10
Fibro-adenoma:	18	60

Variable	Studied group (n=30)	
	No	%
<i>Galacto-cele:</i>	2	6.7
<i>Intra-ductal carcinoma:</i>	2	6.7
<i>Lipoma:</i>	3	10

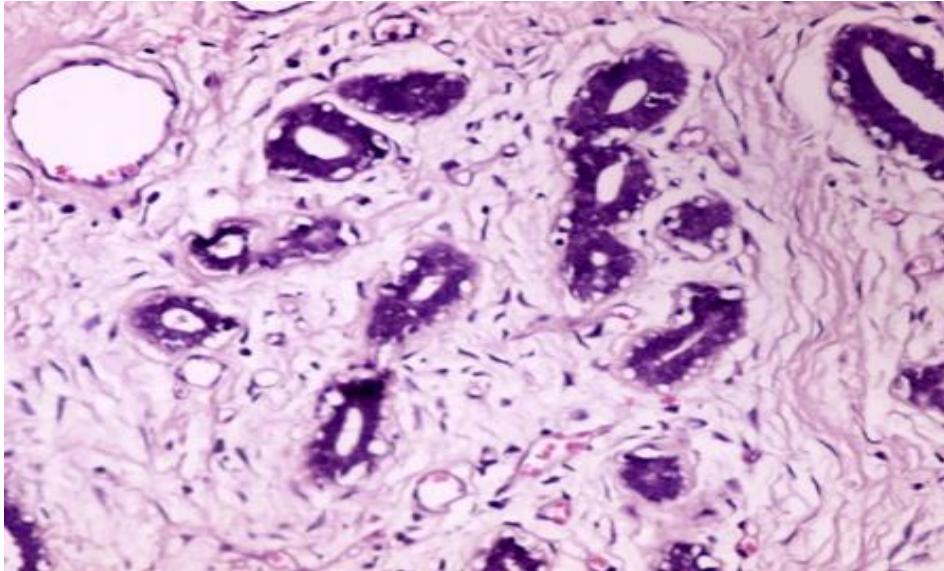


Figure (1) Section in pericanalicular fibroadenoma shows : Proliferated ducts rounded or oval , patent lumen and lined by two layers of cells , outer flattened and inner cubical.

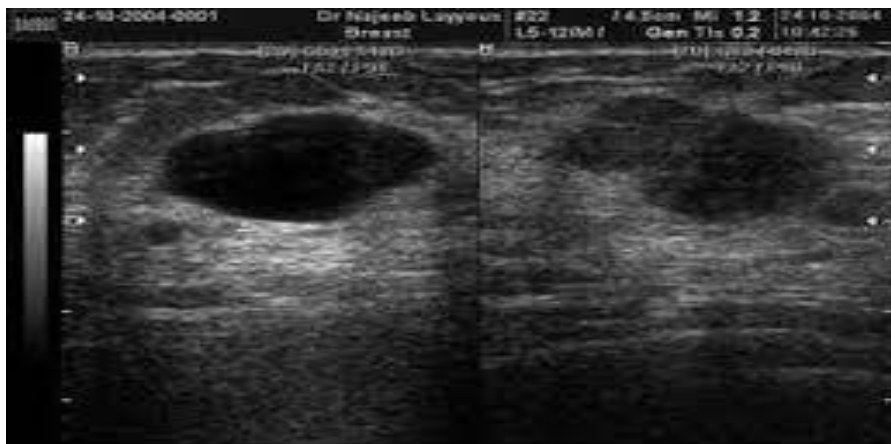


Figure (2) Ultrasound of breast shows fibroadenoma.

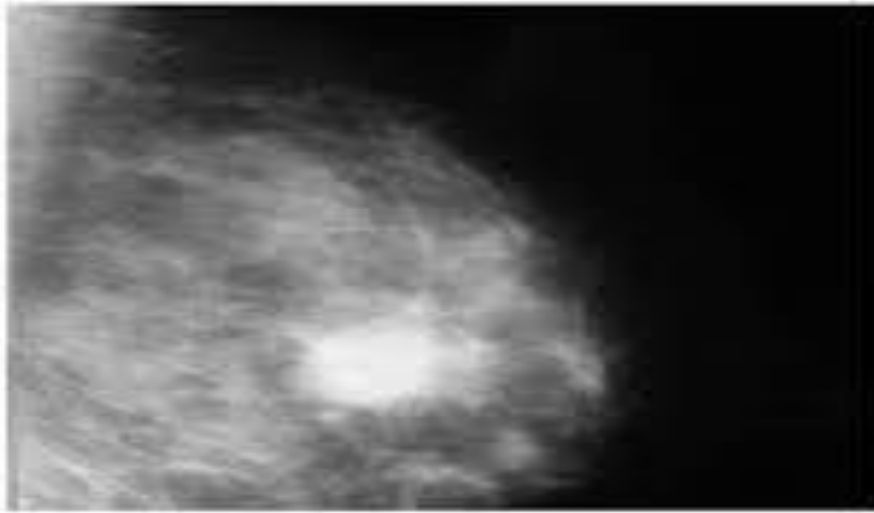


Figure (3) Mamogram of breast shows well defined oval shaped lesion Q fibroadenoma.

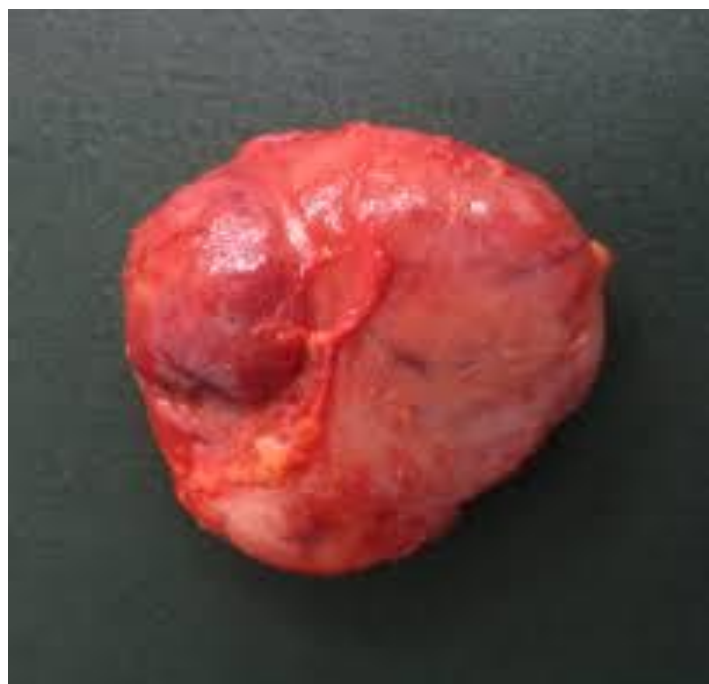

Figure (4) Gross picture of fibroadenoma after excision.

### DISCUSSION

This study included 30 patients with mean age 24 years (range from 16-29 years). This incidence is near to the report of **Egwuonwu et al.[8]** which estimated that the mean age was 22 years, and the study done by **Narayan Das et al.[9]** who mentioned that the mean age of patients was 20 years old.

In our study, in 23 (76.7%) of cases the mass was unilateral, and 7 cases (23.3%) develop bilateral mass, these result is near to the result of **Brijesh.[10]** who reported (85%) of unilateral masses.

In our study, 2 cases (6.7%) were associated with nipple discharge and 3 (10%) cases have palpable axillary lymph nodes, these was near to results of **Brijesh.[10]** who reported 8% of cases associated with nipple discharge and (9%) have associated axillary lymph nodes.

These disagreed with **Chang et al.[11]** who reported no cases were associated with axillary lymph node and 2% associated with nipple discharge.

From the studied group, 10 cases had the mass in right the breast (33.3 %), 13 cases had the mass in the left breast (43.3 %) and it was found bilateral in 7 cases with (23.3 %), this

matches with **Egwuonwu et al.[8]** results where the left breast was affected in (48.9%) of cases.

The upper outer quadrant was affected in 53.3%, the lower outer quadrant was 13.3% and the central (sub areolar) was 23.3%. Multiple fibroadenomas were noted in (16%) of cases, these were nearly the same results reported by **Chang et al.[11]** who stated that the upper outer quadrant was affected in 55.4%, the lower outer quadrant was 20.1%, and the central (subareolar) area was 7.9% from a study carried on 363 patients with breast mass. in study made by **Carty et al.[12]** the upper outer quadrant was affected in (31.3%) of cases.

The clinical provisional diagnosis of fibroadenoma is apparently straight forward given a discrete, smooth, mobile, and non-tender breast lump for our cases it was suspected to be fibroadenoma in 20 cases ( 66.7 % ) , fibroadenosis in 3 cases ( 10 % ) , cyst and duct ectasia in one case for each ( 3.3 % ) and 5 cases were in need for further investigation to reach a clinical diagnosis , these results was near to **Egwuonwu et al.[8]** who reported ( 69 % ) of cases suspected to be fibroadenoma clinically , and ( 22%) other benign disease , while in **Savita's.[13]** study (74%) of cases were suspected to be fibroadenoma .

Considering histopathological examination in our study, 18 cases were fibroadenoma (60%), chronic breast abscess and lipoma were found in 3 cases for each (10 %), duct ectasia, galactocele and intraductal carcinoma were found in 2 cases for each (6.7 %), this matches with **Brijesh.[10]** whose results were (65%) proved fibroadenoma by HPE.

Also **Can't et al.[14]** found that with clinical diagnosis of fibroadenoma there was histological confirmation of fibroadenoma in (68.0%), the remainder having various benign conditions and (1.3%) had carcinoma.

For fibroadenoma, true positive cases were 16 cases, false positive 2 cases, true negative 4 therefore the sensitivity of clinical diagnosis of fibroadenoma 88.9% and specificity was 66.7 % with accuracy 80% with positive predictive value of (80%), this agrees with the results of **Egwuonwu et al.[8]** who reported sensitivity of clinical diagnosis of

fibroadenoma was 93.3% and specificity was 69%.

In the study by **Carty et al.[12]** of the lesions thought to be fibroadenomas preoperatively by clinical breast examination, imaging and cytology histology differed in only (7.5%) out of fibroadenomas and no carcinomas were misdiagnosed. They also noted that the sensitivity of cytology and sonomammography for the diagnosis of fibroadenoma in their study were 84.0% and 98.0%, respectively, with a positive predictive value of 92.5%.

In another study by **Eltahir et al.[15]** documented the diagnostic accuracy of clinical examination for patients presenting to a breast clinic as 88.7%, 99.1%, and 98.5%, respectively, for sensitivity, specificity, and positive predictive value.

### CONCLUSIONS

The sensitivity of clinical diagnosis of giant fibroadenoma in female patients  $\leq 30$  years in our study is good, but the specificity is low. Even though a clinical fibroadenoma is unlikely to be malignant in patients under 30 years, a follow-up is needed in those refusing excision biopsy to detect changes in the lump while still insisting on imaging or fine needle aspiration for cytology or core biopsy to determine histology for future reference.

One can recommend the following:

The sensitivity and specificity of mammography and cytology are higher than that of clinical examination in our study and Conservative management is safe in clinically and cytologically benign breast lump.

So, further studies including larger number of patients and long-term follow up to clarify the risk of recurrence and malignant transformation of benign breast mass.

**7-Conflict of interest:** There is no conflict of interest

**8-Financial disclosures:** Nil.

### REFERENCES

- 1-Sharma, S, Rana and B: Giant Fibroadenoma of Breast: A Diagnostic Dilemma in a Middle Aged Woman. *Adv Cytol Pathol* 2017; 2(4): 00029.
- 2-AlGhamdi, S., Ali, A.G., Ali, S.N. et al.: Giant juvenile fibroadenoma of breast in adolescent girls. *Journal of pediatric surgery case reports* 2018; 28: 33-36.

- 3-Lee, M, Soltanian and H. T: Breast fibroadenomas in adolescents: current perspectives. *Adolescent health, medicine and therapeutics* 2015; 6: 159.
- 4-Chen, C, Gao, D, Luo and L-b: Case Report Multiple and giant juvenile fibroadenoma: a case report and literature review. *Int J Clin Exp Med* 2018; 11(5): 5206-5211.
- 5-Celik, S. U., Besli Celik, D., & Yetiskin and E : Giant juvenile fibroadenoma of the breast: a clinical case. *Arch Argent Pediatr* 2017; 115: e428-e431.
- 6-Hiller, A., Lee, T.J., Henderson, J. et al.: Oncoplastic Reduction Pattern Technique Following Removal of Giant Fibroadenoma. *Eplasty* 2018; 18.
- 7-Alhefdhi and A: Giant Fibroadenoma Mimicking Phylleoyeds Tumor. *Obstet Gynecol Int J* 2017; 6(4): 00213.
- 8- Egwuonwu OA, Anyanwu S, Chianakwana GU and Ihekwoaba EC : Fibro adenoma: Accuracy of clinical diagnosis in females aged 25 years or less. *Niger J Clin Pract* 2016; 19:336-8.
- 9- Narayan Das N, Debbarma A and Debbarma G : A clinico-pathological study of benign breast diseases in rural population. *Int J Res Med Sci* 2014; 2:1067-9.
- 10- Brijesh Th and Vatsala M: Clinic histopathological features of Fibroadenoma Breast in patients less than 20 years of age and its comparison with elder patient. *IOSR Journal of Nursing and Health Science (IOSR-JNHS)*. ISSN 2014; 2320–1940(3): 67-71.
- 11- Chang J.M, Moon W.K, Cho N and Kim S.J: Breast mass evaluation: factors influencing the quality of US elastography. *Korean Radiology* 2016; (259): 59–64.
- 12- Carty NJ, Carter C, Rubin C, Ravichandran D, Royle GT and Taylor I : Management of fibroadenoma of the breast. *Ann R Coll Surg Engl* 2005; 77: 127-30.
- 13- Savita B J, Ishan Jain, Jyoti S and Bharat J : A Clinic pathological study of breast lumps in patients presenting in Surgery OPD in a referral hospital in Madhya Pradesh, Indi. *Int.J. Curr.Microbiol. App.Sci* 2015; 4(8): 919-923.
- 14- Cant PJ, Madden MV, Close PM, Learmonth GM, Hacking EA and Dent DM: Case for conservative management of selected fibro-adenomas of the breast. *Br J Surg* 2007; 74: 857-9.
- 15- Eltahir A, Jibril JA, Squair J, Heys SD, Ah-See AK, Needham G et al.:The accuracy of “one-stop” diagnosis for 1,110 patients presenting to a symptomatic breast clinic. *J R Coll Surg Edinb* 2009; 44: 226-30.

#### TO CITE THIS ARTICLE

Khalil, A., Mohammed, R., Gertallah, L., Ayad, M. Clinical and pathological characteristics of breast giant fibroadenoma among young females. *Zagazig University Medical Journal*, 2021; (1025-1031): -. doi: 10.21608/zumj.2019.14778.1350