

Manuscript ID  
DOIZUMJ-2003-1784 (R1)  
10.21608/zumj.2020.25513.1784**ORIGINAL ARTICLE****Multimodality treatment of cerebral arteriovenous malformations**mohammad ezzat email<sup>1</sup>; Mohamed Ala<sup>2</sup>; Mahmoud M Taha<sup>3</sup>; Tarek Hassan Abdelbary<sup>4</sup><sup>1</sup>assistant lecturer of neurosurgery , zagazig university , Egypt.<sup>2</sup>professor of neurosurgery , ain shams university , Egypt<sup>3</sup>professor of neurosurgery , zagazig university , Egypt.<sup>4</sup>professor of neurosurgery , zagazig university , Egypt**Corresponding author:**

Mohammad ezzat alsayed : assistant lecturer of neurosurgery , zagazig university , Egypt

E-mail :

[dr\\_m\\_ezzat@yahoo.com](mailto:dr_m_ezzat@yahoo.com)

Submit Date 2020-03-31

Revise Date 2020-04-09

Accept Date 2020-04-13

**ABSTRACT****Background:** cerebral arteriovenous malformations (AVMs), vascular lesions in the brain , can cause neurological complications like intracerebral hemorrhage. Treatment options include surgical excision , endovascular embolization , radiosurgery and multimodal therapy. Multimodality treatment uses two or more options to treat the same case, so maximizing the benefits of each option.**Objectives:** The aim is to evaluate outcome of patients with cerebral AVMs by surgery , embolization , radiosurgery and multimodality treatment in neurosurgery Department, Zagazig University Hospitals from May 2017 to May 2019.**Patients and methods:** 42 patients with AVM included 5 cases operated for excision, 23 cases for endovascular embolization, 14 cases for both endovascular embolization and gamma knife radiosurgery. In this study we used single modality approach (surgery or embolization) in 28 cases and multimodality approach (embolization followed by radiosurgery) in 14 cases. Results: multimodality treatment provides a better solution for large AVMs and those with residual nidus following embolization.**Conclusion:** management of AVMs depends on presenting symptoms ,Spetzler-Martin grade (SMG) , patient choice ,and center experience.**Key words:** cerebral arteriovenous malformations, multimodality treatment, ruptured AVM , cerebral hemorrhage, unruptured AVM, stereotactic radiosurgery.**List of abbreviations:** AVMs; arteriovenous malformations. CT(A); computed tomography(angiography). DSA; digital subtraction angiography. ECA; external carotid artery. EE; endovascular embolization. ICH; intracranial hemorrhage. Gy; gray. MRI(A); magnetic resonance imaging(angiography). SMG; Spetzler-Martin grade. SRS; stereotactic radiosurgery.**INTRODUCTION**

Cerebral arteriovenous malformations are considered complex vascular lesions having a tortuous nidus of afferent and efferent vessels connecting one or more draining veins with one or more feeding arteries. The nidus has no intervening capillary bed and connects the venous and arterial sides, and so, it can rupture causing intracranial radiological outcomes of large cohort studies for AVM patients have been created by leading management centers (2). Recent studies showed

hemorrhage(1). Cerebral AVM is not a common lesion, and no guidelines for management have yet been proposed for all AVMs. The current management modalities include observation, microsurgical excision, stereotactic radiosurgery (SRS), endovascular embolization (EE), and multimodality technique, depending on the specific case. Clinical and better outcomes due to using modern techniques and technology. The management guidelines are not always agreed upon across grading systems.

Even if the best management is conservative follow up, the correct modality must be chosen for each case to minimize mortality and morbidity, and maximize patient benefit.(3)

### METHODS

A prospective study of 42 cases with Cerebral arteriovenous malformations either treated in Neurosurgery department, Zagazig University Hospitals, Egypt and Neurosurgery department, Ain Shams university, Egypt during two years duration (from May 2017 to May 2019) for evaluation of the outcome of patients with cerebral AVMs by surgery, embolization, radiosurgery and multimodality treatment.

A written informed consent was taken from all the patients before the start of the study. The study was accepted by the Faculty of Medicine's ethical review committee at Zagazig University and Ain Shams university. The work was carried out for human studies in accordance with the World Medical Association's Code of Ethics (Helsinki Declaration).

All cases evaluated by CT and MRI brain before intervention. It was useful for diagnosis and follow up for ICH caused by cerebral AVMs, as an investigative study for diagnosis after the presentation, for localization of the site of the AVM, associated infarction due to ischemia or associated hydrocephalus.

MRI was done for all patients, and was used as good diagnostic tool in revealing pathological precise location, anatomy, gliosis and edema. MRI aided in the calculation of the AVM diameter as well as detection of AVM nidus configuration. 3D-CTA was available in some patients and was very useful for the surgical planning as it allows delineation of the arterial feeders, the nidus and the draining veins simultaneously.

Intra-arterial digital subtraction angiography (IADSA) is the best tool for AVM evaluation, it was done to major vessels, vertebral arteries, external and internal carotid arteries, to detect any dural blood supply, from ECA and also to detect multiple feeders from any other vessels, in order not to have wrong data about the AVM treated.

**Surgical resection:** All Patients received general anesthesia under standard monitoring. After positioning, Craniotomy is designed according to the AVM nidus size and location using a high-speed drill or manual drill. After dural opening. Careful and extensive sharp dissection of the fissures, sulci, and subarachnoid cisterns to control the proximal portion of the feeding vessels. Stepwise temporary-clip application technique is followed for the dissection and closure of the feeding arteries. Blunt dissection of the nidus with

division of arterial feeding at their entry point. Coagulation and division of the draining veins.

**Endovascular embolization:** All cases underwent therapeutic embolization by transarterial route under general anesthesia. Common femoral artery access was obtained using a 6-F sheath, arteriogram and superselective arteriogram were done to choose targets for embolization. Once the microcatheter has been placed in an appropriate position. Angiogram projections were selected to show the tip of the microcatheter and its relationship to any curves in the feeding arteries and any normal vessels proximal to it and deposition of embolic material (Onyx) could be started.

**Stereotactic radiosurgery:** Gamma Knife is the radio surgical technique used in our study. Frame is applied to the head, MRI and MR angiography were performed then Creation of a treatment plan by AVM target identification and dosing which ranged from 18-22 Gy in our study.

**Inclusion criteria:** were specified for each procedural intervention independently.

**Surgical management;** Patient is fit for surgery, AVM is surgically accessible, Need for urgent management ( ICH evacuation ) and Surgeon's experience.

**Endovascular embolization;** AVM has an appropriate endovascular access to the nidus, Patient is not fit for surgery, Patient refusing other modalities, Clinical indicator for embolization treatment: Reducing the neurological deficit due to steal and Decrease the intensity of headache and AVM is not surgically accessible.

**Stereotactic radiosurgery;** Patient is not fit for surgery, Patient refusing other modalities, AVM is not surgically accessible, AVM size is appropriate for radiosurgery, AVM is considered low risk of bleeding during the latent period radiosurgery and AVM nidus is diffuse.

**Multimodal approach (Embolization followed by radiosurgery);** Patient is not fit for management by single modality, Need for preoperative obliteration of deep feeding vessels, Need for reduction in the volume of the AVM nidus before radiosurgery and Need for obliteration of external carotid feeders before radiosurgery.

**Exclusion criteria: For all :** Extremes of age (younger than 2 years & older than 80 years) and poor medical condition **Surgical management;** Patient is not fit for surgery, Patient declined surgery and preferred another modality, AVM is surgically inaccessible Unruptured AVM and Easily accessible for endovascular embolization.

**Endovascular embolization;** Patient is fit for another single modality, Patient declined embolization and Complicated vascular anatomy.

**Stereotactic radiosurgery:** AVM is surgically accessible, Need for rapid eradication of the risk of hemorrhage, AVM nidus is too large for radiosurgery and Diffuse AVM nidus.

**Combined approach;** Patient is fit for single modality management and Patient is designated for conservative management.

**Statistical methodology:** Statistical package for social science SPSS was used for analysis of the clinical and procedural data collected. Description of all qualitative and quantitative variables , Comparison of quantitative variables was done by T-test (student t-test of two independent samples to compare between two quantitative variables) paired T-test or nonparametric test, as appropriate and Comparison of qualitative variables was done by Chi-square (X<sup>2</sup>) test.

Significance level (P value = probability value).

P < 0.01 highly significant test, P > 0.05

insignificant test and P < 0.05 significant test.

### RESULTS

42 patients were treated in Zagazig university hospitals and in Ain-shams university hospitals as described in the next table: Table (1) Comparison between the studied groups regarding demographic characteristics, presentation and modality technique

Table (2) Comparison between the studied groups regarding clinical and radiological outcome:

There is statistically non-significant difference between the studied groups regarding occurrence of complications in form of rebleeding or neurological deficit.

There is statistically non-significant difference between the studied groups regarding radiological outcome Table (3) Comparison between the studied groups regarding nidal size and SMG:

There is statistically significant difference between the studied groups regarding size (higher in multimodality group).

There is statistically non-significant difference between the studied groups regarding SMG (higher in patients underwent multimodality technique).

This table denote multimodality technique was useful in AVM cases with larger nidal size and higher SMG.

**Illustrated cases:** Case no 1, male patient , 11 years old , presented with ICH ( left frontal) associated with seizures and right sided weakness.

**Table (1) Comparison between the studied groups regarding demographic characteristics, presentation and modality technique:**

Demographic characteristics	Technique			Test	
	Surgery N=5(%)	Embolization N=23(%)	Multimodality N=14(%)	χ <sup>2</sup>	p
<b>Gender:</b>					
Female (18)	2 (40)	10 (43.5)	6 (42.9)	0.02	0.99

ICH was managed conservatively. He was diagnosed by imaging as left posterior frontal AVM . He was managed by endovascular embolization using onyx. He was improved clinically and we achieved complete radiological obliteration in the follow up DSA after 6 months.

Figure 1: A,B ;Left carotid angiogram lateral & AP views showing left parietal AVM nidus supplied by M4 branch and drained into superior sagittal sinus. -- C,D: Postembolization left carotid angiogram showing complete obliteration of AVM nidus follow up DSA 6 months

Case no 2, male patient, 31 years old , presented with ICH ( left frontal) associated with disturbed conscious level and right sided weakness . ICH was evacuated surgically. He was diagnosed by imaging as left frontal AVM. He was managed by surgical excision. He was improved clinically and we achieved complete radiological excision.

Figure 2 : A; preoperative DSA LT frontal nidus – B ; follow up CTA 6 months excised nidus and one aneurysm clip

Case no 3, male patient , 28 years old , presented with IVH associated with disturbed conscious level. He was managed conservatively until conscious level improved. He was diagnosed by imaging as right parietoccipital AVM . He was managed by endovascular embolization using onyx that achieved incomplete radiological obliteration in the follow up DSA so he was referred to a gamma knife center and performed a single session of radiosurgery 3 months following embolization. Follow up DSA, one year later, revealed complete obliteration.

Figure 3: A : initial DSA LT showing occipital nidus – B ; follow up DSA 6 months post emolization (onyx) showing residual nidus – C ; one year follow up DSA postradiosurgical showing obliterated nidus

Case no 4, male patient , 29 years old , presented with RT parietal ICH and IVH associated with disturbed conscious level. ICH and IVH were managed conservatively until conscious level improved. The patient had underwent two sessions of endovascular embolization using onyx with 3 months interval.

Figure 4 : A,B; initial DSA showing RT parietal nidus – C,E ; following first session embolization – D,E following second session embolization.

Demographic characteristics	Technique			Test	
	Surgery N=5(%)	Embolization N=23(%)	Multimodality N=14(%)	$\chi^2$	p
Male (24)	3 (60)	13 (56.5)	8 (57.1)		
<b>Age groups:</b>					
Young age (<18)	0 (0)	5 (21.7)	5 (25.7)	5.35	0.245
middle age (18-50)	4 (80)	17 (73.9)	9 (64.3)		
Old age (>50)	1 (20)	1 (4.3)	0 (0)		
<b>Presentation:</b>					
ICH	4 (80)	17 (73.9)	8 (57.1)	5.878	0.437
Neurological deficit	0 (0)	2 (8.7)	1 (7.1)		
Seizures	1 (20)	2 (8.7)	5 (35.8)		
Headache	0 (0)	2 (8.7)	0 (0)		
<b>GCS:</b>					
Mean $\pm$ SD	12.4 $\pm$ 1.95	13.57 $\pm$ 1.08	13.86 $\pm$ 1.17	2.634	0.085
Range	11 – 15	12 – 15	12 – 15		

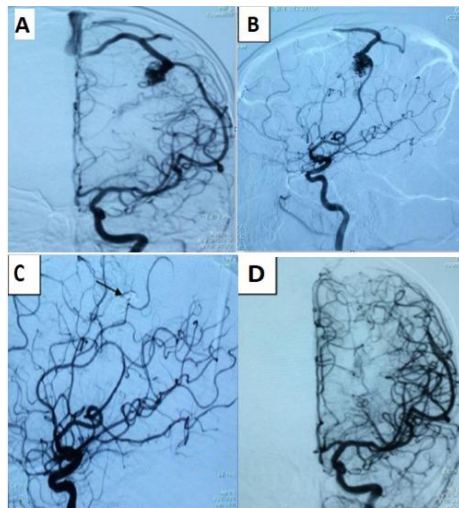
**Table (2) Comparison between the studied groups regarding clinical and radiological outcome:**

complications	Technique			Test	
	Surgery N=5(%)	Embolization N=23 (%)	Multimodality N=14(%)	$\chi^2$	p
Absent	4 (80)	21 (91.3)	12 (92.9)	0.913	0.663
Present	1 (20)	2 (8.7)	2 (7.1)		
Rebleeding	0 (0)	1 (50)	1(50)		
Neurological deficit	1 (20)	1 (50)	1 (50)		
Improved	1 (100)	2 (100)	2 (100)		
<b>Radiological outcome</b>					
<b>Complete</b>	5 (100)	21 (91.3)	12 (85.7)	Fisher	>0.999
<b>Residual</b>	0 (0)	2 (8.7)	2 (14.3)		

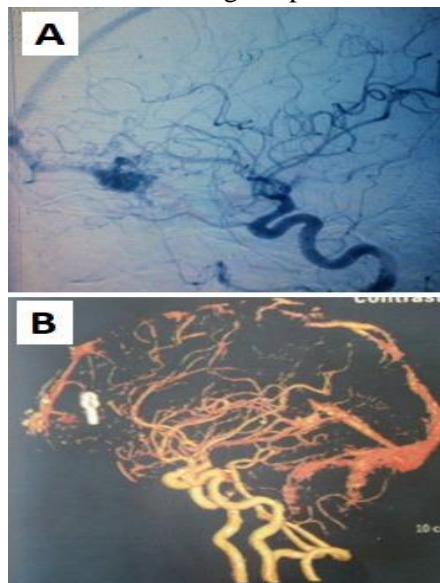
**Table (3) Comparison between the studied groups regarding nidal size and SMG:**

	Technique			Test	
	surgery N=5(%)	Embolization N=23 (%)	Multimodality N=14(%)	t	p
<b>Size</b>					
Large	0 (0)	1 (4.3)	4 (28.6)	7.937	0.087
Medium	3 (60)	14 (60.9)	9 (64.3)		
Small	2 (40)	8 (34.8)	1 (7.1)		
<b>SMG:</b>					
Mean $\pm$ SD	2.4 $\pm$ 0.89	3.09 $\pm$ 0.73	3.71 $\pm$ 0.99	-2.734	0.01*
Range	2 – 4	2 – 5	2 – 5		
<b>SMG:</b>					
<b>2</b>	4 (80)	5 (21.7)	1 (7.1)	15.885	0.012*
<b>3</b>	0 (0)	12 (52.2)	6 (42.9)		
<b>4</b>	1 (20)	5 (21.7)	3 (21.4)		
<b>5</b>	0 (0)	1 (4.3)	4 (28.6)		

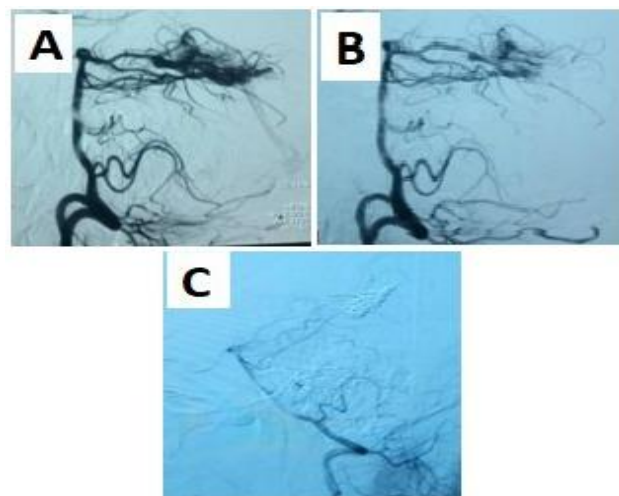




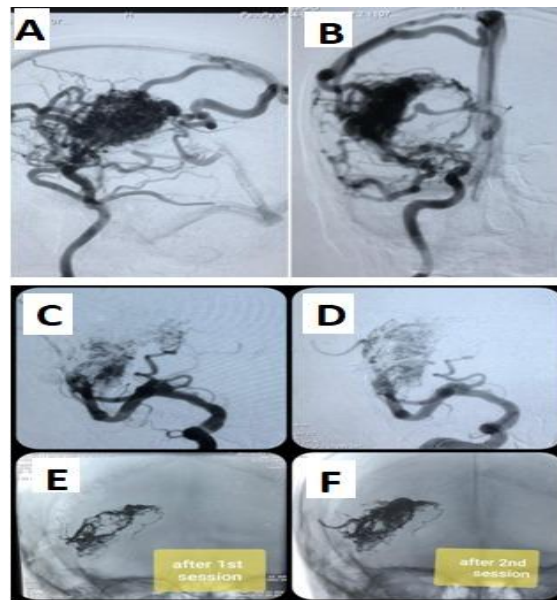
**Figure 1 :** A,B ; AP and Lat DSA showing LT parietal nidus – C,D ; follow up DSA 6 months



**Fig Figure 2 :** A; preoperative DSA LT frontal nidus – B ; follow up CTA 6 months excised nidus and one aneurysm clip.



**Figure 3:** A : initial DSA LT showing occipital nidus – B ; follow up DSA 6 months post embolization (onyx) showing residual nidus – C ; one year follow up DSA postradiodurgical showing obliterated nidus



**Figure 4 :** A,B; initial DSA showing RT parital nidus – C,E ; following first session embolization – D,E following second session embolization

### DISCUSSION

Cerebral AVMs are relatively uncommon but may cause neurological complications up to death . Treatment options are five : conservative , surgical excision , endovascular embolization , radiosurgery or multimodal therapy . Each mode of treatment has its benefits and risks . The lesion can be followed conservatively with some risk of developing intracranial hemorrhage , neurological deficit or seizures . The main goal of cerebral AVMs management is elimination of bleeding risk by complete obliteration or excision.

Each therapeutic modality has its specific advantages and disadvantages. Factors influencing its performance include the medical environment, amount of training, and the operator skills. The physician who decide the management plan must be familiar with the AVM case. Decision making depends on the patient’s current symptoms, clinical history, AVM angioarchitecture, hemodynamics and morphology. Risk factors for hemorrhage include previous bleeding, singular or even impaired venous drainage, intranidal aneurysms . Radiosurgery is the least invasive tool followed by endovascular one. Surgery is the best tool in the Occlusion capacity. surgery and embolization have a rapid efficacy, while radiosurgery has a bleeding risk during the latent period.

Surgery and radiosurgery have a Long-term reliability. embolization is Independent from the nidal size, while surgery and radiosurgery are size dependent.

Embolization is Independent from brain functionality. Radiosurgery is Independent from

angio-architecture. Surgery is Independent from blood flow.

This clinical study presents an analysis of the qualities of the three tools used in treatment of cerebral AVMs. We tried to evaluate these modalities as regard procedural invasiveness, speed of efficacy, occlusion capacity and long-term reliability. We analyzed the clinical and angioarchitectural outcomes as well as the complications resulting from management of 42 patients harboring cerebral AVMs.

Our study was conducted on 42 patients diagnosed to have cerebral AVMs .The demographic distribution was similar to the previous studies reflecting the common epidemiological distribution that the disease exhibit. In our study the male: female ratio was 1.3 and this was similar to what be demonstrated by *Hofmeister C et al., ApSimon HT et al. and Al-Shahi R et al.*(4,5,6). Although other studies as *Gupta et al. and Lopes et al.*(7,8) concerning gender distribution has revealed more female predilection with a female: male ratio 1.1:1.This difference in sex predilection has no impact on the final results but in a part reflecting the sporadic nature of cerebral AVMs with no obvious pattern of genetic predisposition and inheritance.

The mean age of patients was **28.05 years** with more than **60%** of patients **<30 years** and this age distribution was similar to what be demonstrated in *Gupta et al. and Lopes et al.* (7,8)The proportion of patients **> 50 years** was **8%** may be partially explained by the diagnostic bias, i.e. hemorrhagic strokes in the elderly cases do not always appear in angiographic (including CTA or

MRA) examination, and some AVM bleeding in this age group are misjudged as spontaneous intracranial hemorrhages.

Hemorrhage was the most common presenting symptom among patients enrolled in our study occurring in 69% which was similar to that in *Hillman(9)* (69.6%) and more than that in *Crawford PM(10)*, *Gupta et al.* and *Lopes et al.* (64%) followed by seizures in 19%, focal deficits in 7.2% and headache in 4.8%.

On the other hand, more recent patient series as in this meta analysis, involving 2086 patients, conducted by *Zhao et al.(11)* reported a frequency of 43% for the hemorrhagic presentation of AVMs. Headache was the second common clinical presentation and constituted 25%. Seizures occurred in 17% while neurological deficits occurred in 9%. This actually reflects the fact that the increasing availability of neuroimaging is gradually changing the pattern of symptomatology of AVM presentation towards diagnosis in the absence of hemorrhage.

Hemorrhagic stroke due to AVM rupture has remained the single most common presenting symptom confirming the associated epidemiological importance of cerebral AVMs due to related mortality and morbidity and all studies concerning AVMs are always will be closely related to prediction of risk of bleeding and prevention of rebleeding.

All patients included in our study were supratentorial AVMs except one patient with posterior fossa AVM. Supratentorial AVMs were distributed throughout both cerebral hemispheres.

*Deruty et al.(12)* described a location distribution of 91% for supratentorial AVMs and 9% for posterior fossa AVMs. The location distribution of cerebral AVMs in *Gupta et al.(7)* was 92% supratentorial and 8% posterior fossa.

In our study the AVMs size ranged from 1.5 cm to 7 cm. AVMs were categorized into 3 groups according to size: 26.2% were small sized AVMs (<3 cm diameter), 61.9% were medium sized AVMs (3-6 cm diameter) and 11.9% were large sized AVMs (>6 cm diameter). In *Gobin et al.* there was 10.4% small, 77.6% medium, and 12% large. In *Schaller et al.(13)* series of AVM patients 52% were <3cm, 43.3% ranged from 3-6cm and 4.7% were >6cm.

64.3% of our patients were located in eloquent brain areas. These records coincided with those of *Hartmann et al.(14)* that recorded AVM eloquent location in 60% of cases, whereas, *Pikus et al.(15)* recorded 58%. 33.3% of our patients had venous drainage into the deep venous system of the brain. *Pikus et al.* had a rate of 38% deep venous

drainage while *Hernesniemi et al.(16)* had a rate of 45%.

In our study, AVMs were distributed as regard Spetzler Martin grade(SMG), with 23.8% being grade II, 34.4% being grade III, 42.9% being grade IV and 11.9% being grade V.

*Deruty et al.(12)* in their series involving the three management tools of cerebral AVMs they used microsurgery alone in 31% of patients, radiosurgery alone in 23% of patients, endovascular embolization alone in 8% of patients, combined embolization and microsurgery in 16.5% of patients, combined embolization and radiosurgery in 16.6% of patients and finally radiosurgery followed by surgical resection in 5% of patients.

## CONCLUSIONS

Cerebral AVMs are rare lesions, so, their management is difficult. Proper assessment of each case is important to choose the proper method of treatment.

Onyx embolization could be a curative option with accepted rates of mortality and morbidity.

The introduction of detachable tip catheters and Onyx had increased the rate of endovascular cure and decreased the risks associated with management.

Cerebral AVMs suitable for curative Onyx embolization should be selected by analysing the angioarchitectural characteristics of the treated AVM. proper positioning of intracatheter tip with slow, controlled injections of onyx that avoid the draining veins and retrograde reflux can minimize the procedural risk even in eloquent locations.

For curative endovascular embolization, the AVM nidus should be small sized (< 3 cm), supplied by one large arterial feeder, with clear proximal parts of the draining veins, and not having a deep location. For the cases that are not having these criteria, embolization should be considered as first step for other modality of management (surgical excision or radiosurgery) or palliative.

Multimodality management should be used to completely obliterate an AVM. Partial treatment with a single technique does not eliminate bleeding risk and carries procedure risk for the patient. Multimodality treatment plays a helpful role in larger lesions (SMG III or V) for which complete obliteration is the goal. The overall risk of therapy will be reduced with combined techniques.

Declaration of interest

The authors report no conflicts of interest. The authors alone are responsible for the content and writing of the paper.

## REFERENCES

1. **Al Awar O and Patel U J:** Pathophysiological Principles of Cerebral Arteriovenous Malformations, Brain Arteriovenous Malformations, p:51-60, Springer, 2017
2. **Pollock B.E., Storlie C., Link M.J., Stafford S.L., Graces Y.I., Foote R.L.:** Comparative analysis of arteriovenous malformation grading scales in predicting outcomes after stereotactic radiosurgery. *J Neurosurg.* 2017;126(3):852–8.
3. **Derdeyn, C. P., Zipfel, G. J., Albuquerque, F. C., Cooke, D. L., Feldmann, E., Sheehan, J. P., et al.:** Management of Brain Arteriovenous Malformations: A Scientific Statement for Healthcare Professionals From the American Heart Association/American Stroke Association. *Stroke.* 2017;48:e200–e224.
4. **Hofmeister C, Stapf C, Hartmann A, Sciacca P.R., Mansmann U., terBrugge K. et al.** Demographic, morphological, and clinical characteristics of 1289 patients with brain arteriovenous malformation. *Stroke.* 2000;31:1307–10.
5. **ApSimon HT, Reef H, Phadke RV, Popovic E.A.:** A population-based study of brain arteriovenous malformation: long-term treatment outcomes. *Stroke.* 2002;33:2794–800
6. **Al-Shahi R, Fang JS, Lewis SC, Warlow C.P.:** Prevalence of adults with brain arteriovenous malformations: a community based study in Scotland using capture-recapture analysis. *J Neurol Neurosurg Psychiatry.* 2002;73:547–51.
7. **Gupta R., Adeeb N., Moore J.M., Motiei-Langroudi R., Griessenauer C.J., Patel A.S., et al.:** Validity assessment of grading scales predicting complications from embolization of cerebral arteriovenous malformations. *Clinical Neurology and Neurosurgery* 151 (2016) 102–107.
8. **Lopes DK, Moftakhar R, Straus D, Munich SA, Chaus F, Kaszuba MC:** Arteriovenous malformation embocure score:AVMES. *J Neurointerv Surg* 8:685–691, 2016.
9. **Hillman J:** Population-based analysis of arteriovenous malformation treatment. *J Neurosurg* 95:633-637, 2001
10. **Crawford PM, West CR, Chadwick DW, Shaw MD.:** Arteriovenous malformations of the brain: natural history in unoperated patients. *J Neurol Neurosurg Psychiatry.* 1986;49:1–10.
11. **Zhao J, Wang S, Li J, Qi W, Sui D , Zhao Y.:** Clinical characteristics and surgical results of patients with cerebral arteriovenous malformations. *Surg Neurol* 63:156-161; discussion 161, 2005
12. **Deruty R, Pelissou-Guyotat I, Morel C, Bascoulergue Y, Turjman F:** Reflections on the management of cerebral arteriovenous malformations. *Surg Neurol* 50:245-255; discussion 255-246, 1998
13. **Schaller C, Schramm J, Haun D.** Significance of factors contributing to surgical complications and to late outcome after elective surgery of cerebral arteriovenous malformations. *J Neurol Neurosurg Psychiatry.* 1998;65:547–54.
14. **Hartmann A, Pile-Spellman J, Stapf C, Sciacca RR, Faulstich A, Moher JP, et al.:** Risk of endovascular treatment of brain arteriovenous malformations. *Stroke* 33:1816-1820, 2002
15. **Pikus HJ, Beach ML, Harbaugh RE:** Microsurgical treatment of arteriovenous malformations: analysis and comparison with stereotactic radiosurgery. *J Neurosurg* 88:641-646, 1998
16. **Hernesniemi JA, Dashti R, Juvela S, Vaart K, Niemela M, Laakso A:** Natural history of brain arteriovenous malformations: a long-term follow-up study of risk of hemorrhage in 238 patients. *Neurosurgery* 63:823-829; discussion 829-831, 2008.

**How to cite**

Ezzat, M., Ala, M., M Taha, M., Abdelbary, T. Multimodality treatment of cerebral arteriovenous malformations. *Zagazig University Medical Journal*, 2022; (89-96): -. doi: 10.21608/zumj.2020.25513.1784