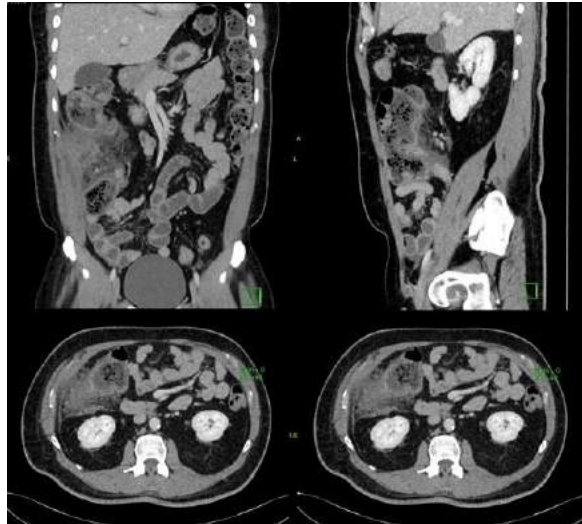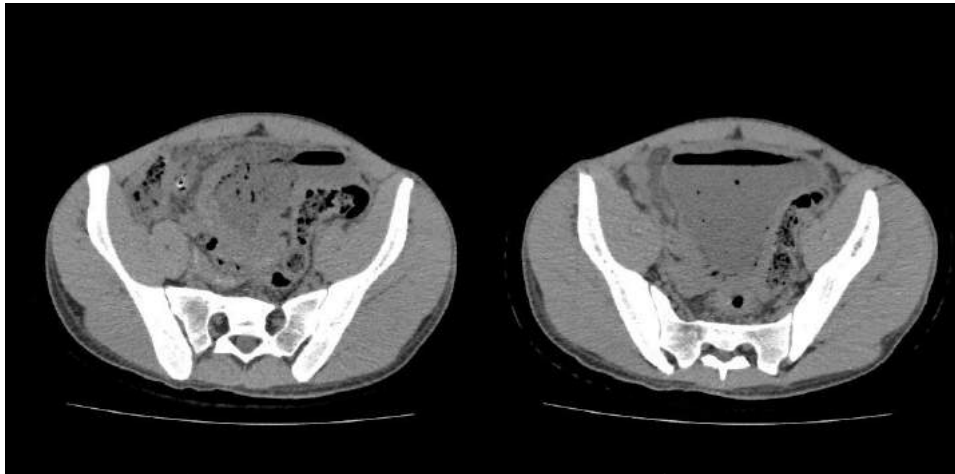
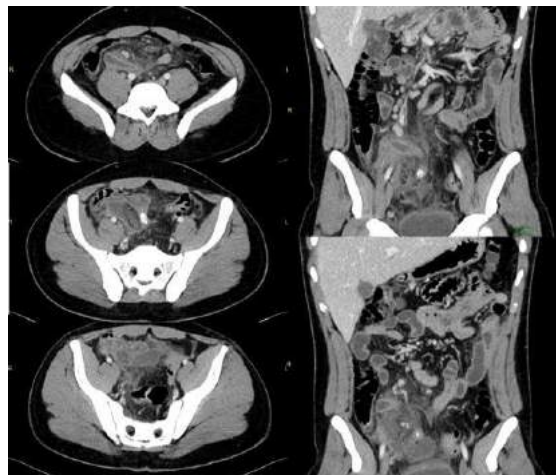


Case NO. 1 Acute appendicitis with appendicoliths



Case NO. 2 intraperitoneal abscess formation closely related to the appendix



Case NO. 3 Perforated appendix with appendicoliths and surrounding inflammatory process.