

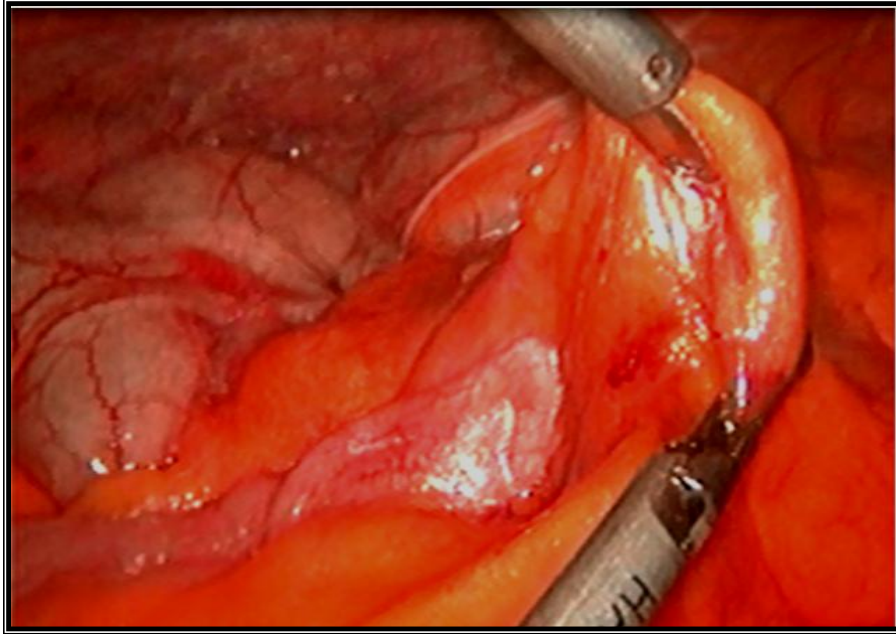Fig. (3) Medial approach dissection in. Laparoscopic Rt. Colectomy

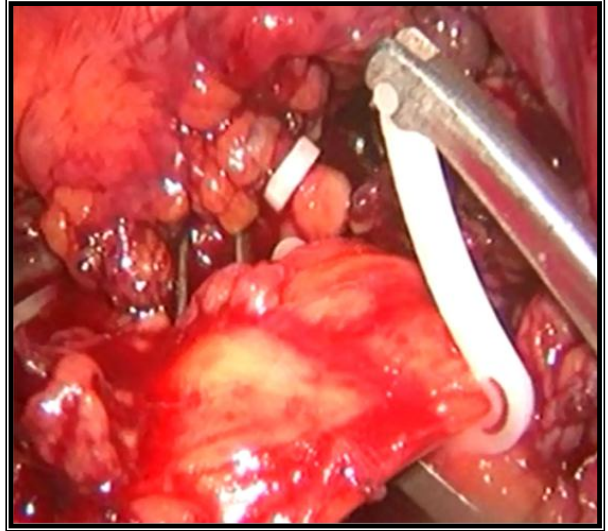
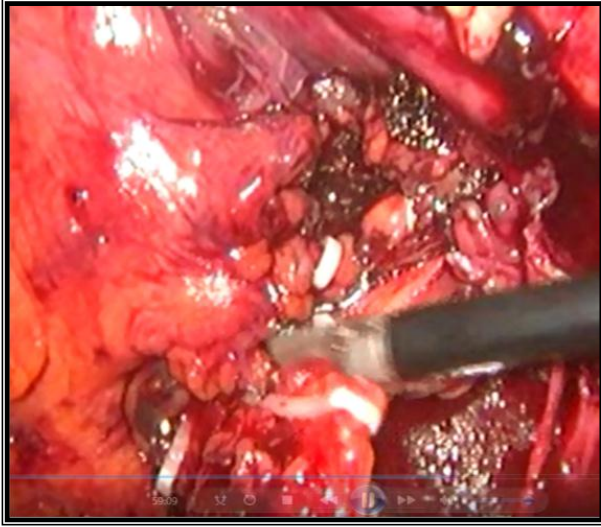


Fig. (4): Dissection & Ligation of right colic vessels.

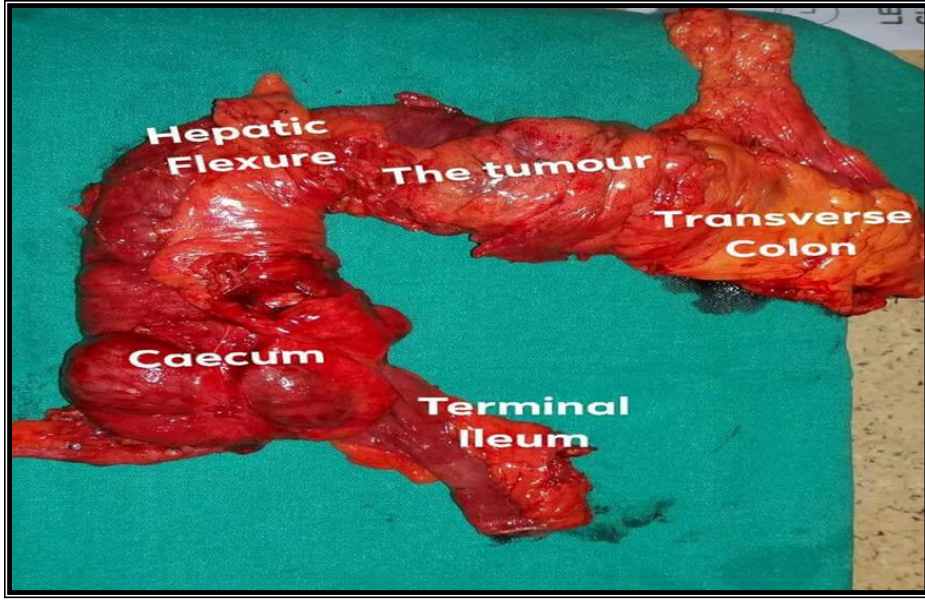


Fig. (22) Specimen for resected transverse colonic carcinoma.