



DOI 10.21608/zumj.2019.13572.1256

ORIGINAL ARTICLE**Mastoid Obliteration In Cholesteatoma Surgery, Different Materials**

Alsayed Abdulmageed Alsayed ^{1*}, Mohamed Kamal Mobashir¹, Said Abouelezz¹, Ahmed Alhady¹

¹Otorhinolaryngology department, faculty of medicine , zagazig university , zagazig, Egypt

***Corresponding author:**

Alsayed abdulmageed
alsayed

Assistant lecturer of
otorhinolaryngology
department, faculty of
medicine , zagazig university
Email:

drsayed.drsayed@gmail.com

| | |
|-------------|------------|
| Submit Date | 2019-06-23 |
| Revise Date | 2019-07-05 |
| Accept Date | 2019-07-06 |

ABSTRACT

Background: The principal advantages of mastoid cavity obliteration are 1) reduced nitrogen-absorbing mucosa in the mastoid cavity preventing recurrence of retraction cholesteatoma in patients with eustachian tube dysfunction, 2) elimination of mastoid cavity preventing accumulation of squamous epithelium and bowel infection . The size of the surgical cavity can be diminished using obliteration to create a small cavity that is self cleaning and easily maintained. Both autologous and synthetic materials have been used for obliteration. Materials such as free graft, fat, cartilage, bone chips, bone pâté, hydroxyapatite, and periostio-muscular flaps are used. **Aim of work:** To evaluate the benefit from mastoid obliteration in cholesteatoma surgery. **Patients and methods:** This study was applied on 12 patients that have middle ear cholesteatoma.mastoidectomy had been done then obliteration either by natural or synthetic fillers had been done and followed up by DW-MRI **Results:** The patients consisted of 6 females (50%) and 6 males (50%). Their ages ranged from 14 to 52 years old. **Conclusion:** Mastoid obliteration can be used in combination with either the ICW or CWD techniques. It gives favourable long-term results. It is certainly the treatment of choice for persistent dischargeingmastoid cavities.

Keywords: mastoid obliteration ; cavity problems ; recidivism; DW MRI

INTRODUCTION

The choice of surgical procedure for the treatment of middle ear cholesteatoma had been controversial for the past several decades. Canal-wall-up(CWU) and canal-wall-down(CWD) procedures constitute 2 major categories of tympanomastoidectomy. Each of the procedures has its own advantages and disadvantages. [1]

A canal wall-down mastoid cavity represents a major morbidity to patients with chronic ear disease. The consequences include susceptibility to infection with any water exposure, recurrent otorrhea, the need for frequent cleaning, difficulty with the use of conventional hearing aids and vertigo caused by warm or cold air or water exposure. [2]

Mastoid obliteration with reconstruction of the bony external ear canal is a procedure that is used to avoid all these complications.

In 1911, Mosher introduced the concept of mastoid obliteration . [2]

The principal advantages of mastoid cavity obliteration are 1) reduced nitrogen-absorbing mucosa in the mastoid cavity preventing recurrence of retraction cholesteatoma in patients with eustachian tube dysfunction, 2) elimination of mastoid cavity preventing accumulation of squamous epithelium and bowel infection . The size of the surgical cavity can be diminished using obliteration to create a small cavity that is self cleaning and easily maintained. Both autologous and synthetic materials have been used for obliteration. Materials such as free graft, fat, cartilage, bone chips, bone pâté, hydroxyapatite, and periostio-muscular flaps are used. [3]

PATIENTS AND METHODS

Selection of patients

This study was carried out on 12 ears of 12 patients in the Department of Otorhinolaryngology, Head and Neck Surgery, Zagazig University Hospitals from november 2016 through june 2018. Examination and assessment of the cases were performed for a follow up once weekly for 2 months, then monthly for 4 months, then a postoperative DW MRI scanning was done at the end of the 6 months postoperatively.

Statistical Analysis:

The collected data were computerized and statistically analyzed using SPSS program (Statistical Package for Social Science) version 24. Qualitative data were represented as frequencies and relative percentages. Quantitative data were expressed as mean \pm SD (Standard deviation)

Exclusion criteria: Patient with intracranial complications of chronic suppurative otitis media, Patients with external and middle ear abnormalities (congenital or acquired), Medically and surgically unfit patients and Patients who cannot provide informed consent.

Inclusion criteria: Acquired middle ear Cholesteatoma, Congenital middle ear cholesteatoma, Unilateral or Bilateral disease, Primary or revision surgery

Pre-operative evaluation

- Thorough general and ENT examination including otoendoscopy (fig1)
- Audiological assessment.
- High resolution computerized tomography (HRCT) of the temporal bone. (fig2)
- An informed consent had been taken from all the patients in this study.

Surgical techniques

1. Anesthesia: All patients were operated under general anesthesia with controlled hypotensive technique.
2. Skin Preparation: Skin disinfection was done with povidone iodine 10%.
3. Drapping.
4. Injection: This is done by 1/200000 adrenalin lidocain solution injected in the external auditory canal under posterior meatal wall skin, at 6th O'clock and 12th O'clock and postauricular

5. Flaps were designed either anteriorly based (palva), inferiorly or superiorly base flap (fig4A, B)
6. Collecting bone pate, moisturing by antibiotic drops (fig4d)
7. Incision and elevation of the flap:
8. Management of the disease in the middle ear, ether CWU or CWD mastoidectomy was done
9. Attic reconstruction by cartilage to prevent bone pate to escape to middle ear cavity not to induce osteogenesis also if there is defect in posterior meatal wall, should be carefully reconstructed, cortical bone harvested from mastoid tip used to reconstruct PMW in CWD mastoidectomy (fig5a)

The bone p \hat{a} t \acute{e} was carefully placed in the attic and mastoid . The remainder of the mastoid and attic was obliterated with bone p \hat{a} t \acute{e} . or Synthetic material (fig5c)

The skin of the external auditory canal was repositioned on the temporalis fascia and the reconstructed posterior canal wall. This was packed by several pieces of gel foam over the tympanoplasty graft, followed by gauze strip impregnated with ointment (inner pack).

The Palva flap was closed with vicryl sutures (fig5b). - The wound was closed in two layers, interrupted closure was preferable, another gauze strip impregnated with ointment was placed on the external meatus (outer pack). A standard mastoid dressing was applied

Postoperative care:

The patients were discharged home in the operative day with oral analgesic and oral antibiotic (ciprofloxacin in adult or amoxicillin clavulanate in adults allergic to ciprofloxacin and patients under 18 years old) to complete 14-day course. - The mastoid dressing, sutures and the outer pack were removed after one week postoperatively. Antibiotic ear drops were instilled until follow up after another 2 weeks (3 weeks postoperatively) to remove the inner pack. - The patients were instructed to keep the external auditory canal dry. Patient follow up:

All patients were followed up once weekly for 2 months postoperatively, then once monthly for another 4 months by: - Otoendoscopic examination. - DW MRI

study ordered at the end of the 6 months of the follow up.(fig3) - Audiological assessment with pure tone audiogram after 6 months.

Follow up: The total follow up period was 12 months.

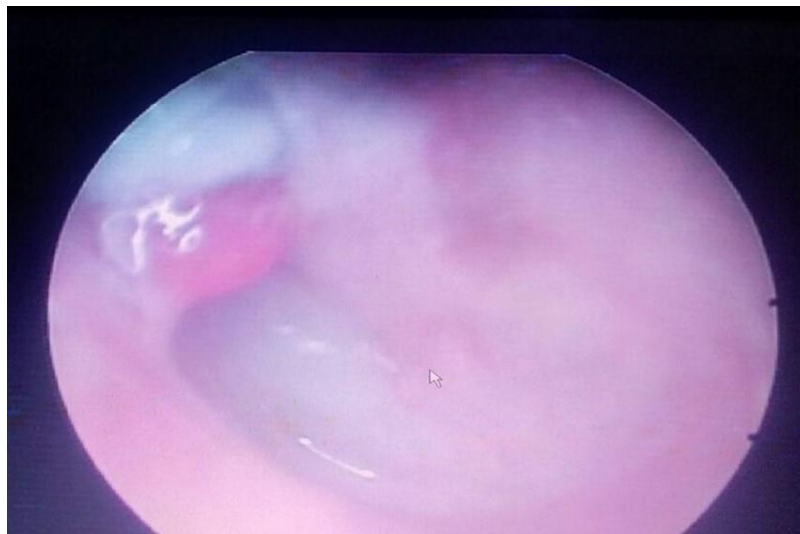It included:-

- Systemic antibiotics for 2 weeks
- Removal of the dressing and the stitches after 1 week, then application of topical ear drops for 2 weeks.

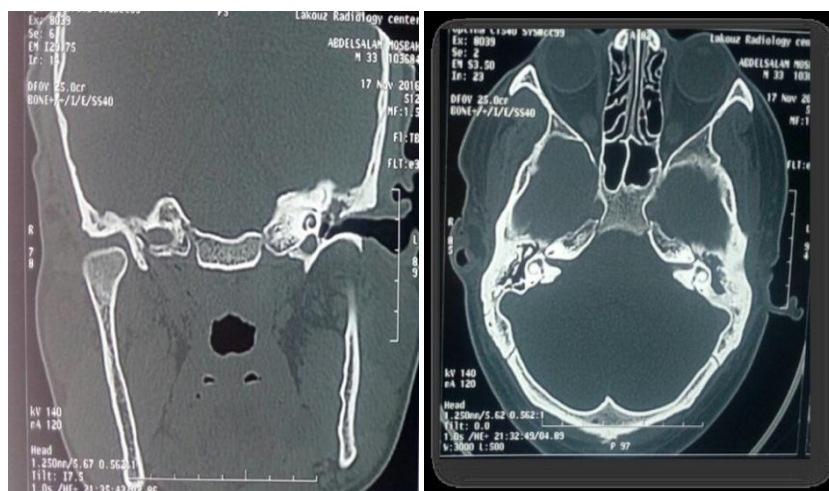
-Patients followed strictly in the early post operative period with stress on water precautions.

-Otoscopic and otoendoscopic examinations were done weekly for the first month, then monthly in the first 3 months, then every 3 months afterwards with meticulous removal of any debris or discharge from the external auditory canal.

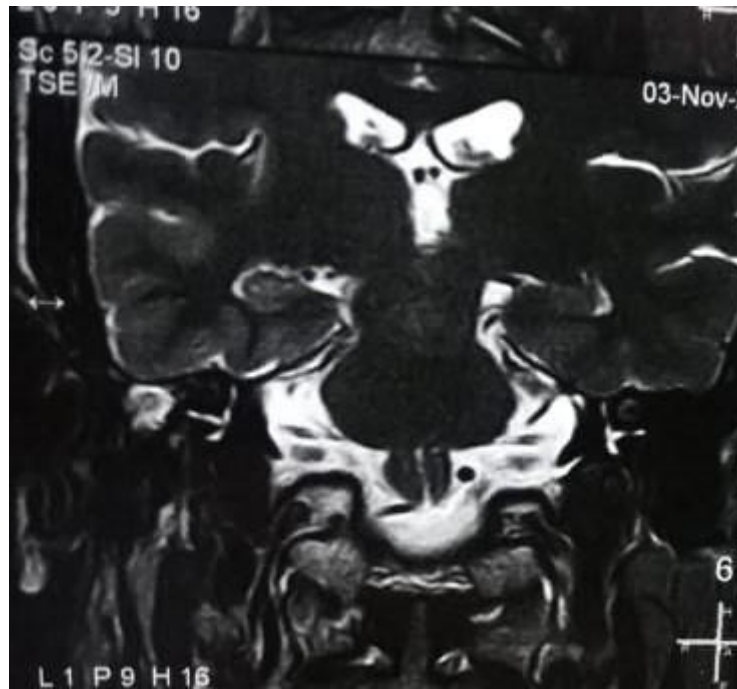-Pure tone audiometry and DW-MRI temporal bone are done 6 mo postoperative.



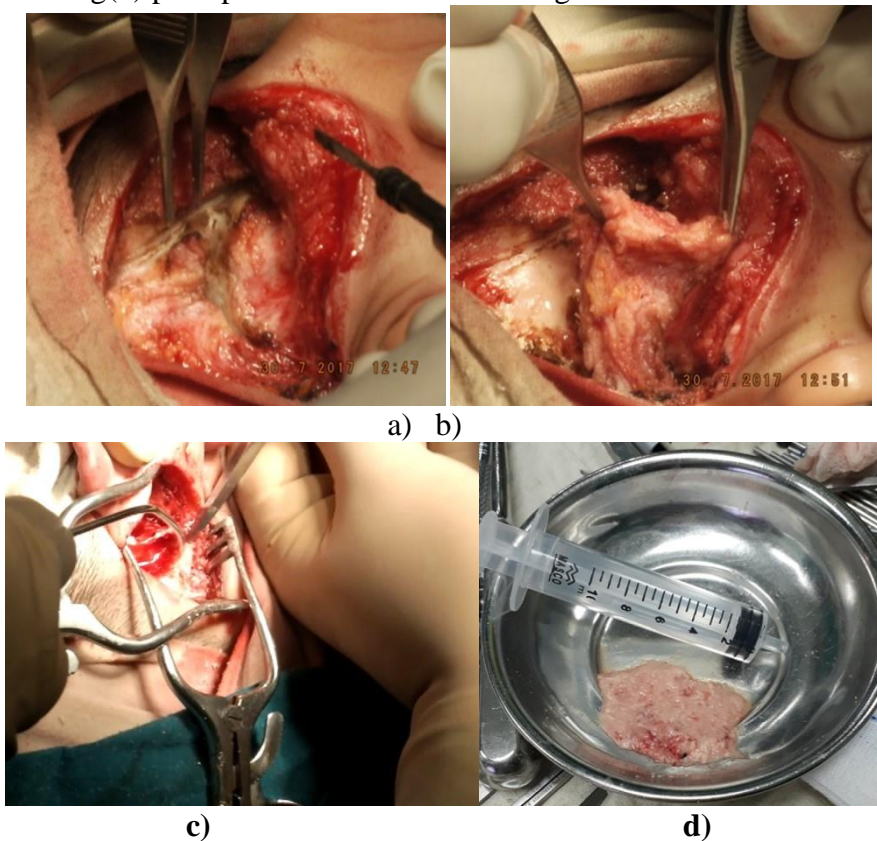
Fig(1)preoperative otoendoscopy



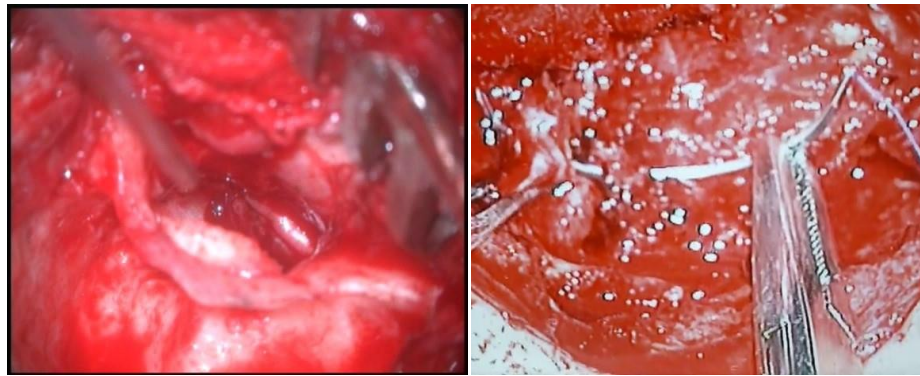Fig(2) (A) preoperative HRCT temporal bone coronal view showing It attic opacity (b) preoperative HRCT temporal bone axial view showing It attic and antrum opacity



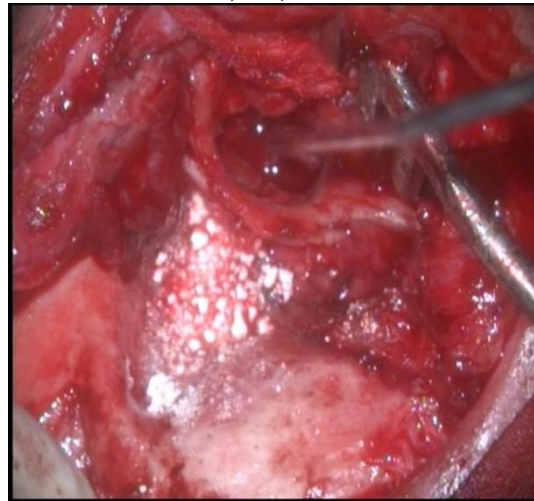Fig(3) postoperative DW MRI showing rt recidivistic lesion



Fig(4) (a,B) flap design
(a) Cortical bone harvesting
(b) Collected bone pate`



a) b)



c)

Fig (5) (a) PMW reconstruction, (b) flap suturing , (c) obliterated cavity by HA granules

RESULTS

This study was carried out on 12 ears of 12 patients in the Department of Otorhinolaryngology, Head and Neck Surgery, Zagazig University Hospitals from November 2016 through June 2018. The patients consisted of 6 females (50%) and 6 males (50%), their ages ranged from 14 to 52 years. The average age at the time of study was 25.9 ± 9.2 years.

Intraoperative difficulties:

- Revision cases (3 cases, 25%) due to decreased amount of collected bone pate , decreased muscle volume and disturbed anatomy
- Extensive cholesteatoma especially toward cortex as bone pate collection was stopped earlier resulting in decreased amount which was overcome by burring in root of zygoma or mastoid tip. Dural injury during burring has occurred in one patient (8.3%), and the defect was closed with bone wax and gel

foam with completion of the surgical procedure.

- Difficult remodeling cortical bone to close PMW defect
- No intraoperative facial nerve injury or sigmoid sinus injury was found.

Through follow up:

- All patients were followed up once weekly in the first 2 months postoperatively, then once monthly. The duration of follow up ranged from 7 to 19 months.
- No symptoms suggestive of clinical inflammation in the operation area, such as erythema, swelling, tenderness. In addition, there was no bleeding or any other abnormality in the site of operation .
- One patient (8.3%) whose cavity was obliterated by bone pate only had infection-related signs in the incision site as discharge and gapping for about 3 weeks postoperatively (table 2), patient readmitted.

The infection responded to conservative treatment, in the form , IV systemic antibiotic and topical antibiotic ointment, and then the site of incision healed by secondary intention.

- Four patients (33.3%) complained from mild dizziness for about 2 to 4 months

postoperatively which subsided gradually and all of them improved spontaneously without medication (table 2). No facial nerve paralysis was detected in any patient during postoperative follow-up period.

Table (1): Type of fillers used in the studied population

| | Frequency | Percent |
|-----------------|-----------|---------|
| Bone pate | 8 | 66.7 |
| flaps | 8 | 66.7 |
| fascia | 3 | 25.0 |
| cartilage | 6 | 50.0 |
| Cortical bone | 2 | 16.7 |
| hydroxyapatite | 2 | 16.7 |
| Bioactive glass | 1 | 8.3 |

Table (2): Complications

| | Frequency | Percent | |
|---------------|------------------------------|---------|------|
| Complications | Non | 20 | 83.3 |
| | Vertigo | 3 | 12.5 |
| | Auricular Retraction | 1 | 4.2 |
| | Periorbital Edema, Emphysema | 1 | 4.2 |
| | Wound Infection | 1 | 4.2 |

DISCUSSION

The advantages and disadvantages of intact canal wall mastoidectomy (ICW) and canal wall down mastoidectomy (CWD) for cholesteatoma are well documented. It is generally accepted that the CWD technique has lower residual and recurrent cholesteatoma rates, but is sometimes accompanied by mastoid cavity problems such as discharge, crust accumulation , dizziness and water intolerance mastoid obliteration is that it combines the advantages of ICW and CWD techniques. Obliteration of the mastoid cavity was first reported in 1911 by **Mosher** using a superiorly based musculoperiosteal flap. The technique was modified and popularized by **Palva** in the 1960s using the anteriorly (meatally) based musculoperiosteal flap. Then, the concept of mastoid cavity obliteration has been taken up by many otologists. The majority of

obliteration techniques consist of either local flaps (muscle, periosteum, or fascia) or free grafts (bone, cartilage, hydroxyapatite, and so on) [4]. Mosher’s original description was that of a superiorly based postauricular soft tissue flap.

Kisch, [5] described the use of a pedicled temporalis muscle flap that was expanded on by **Rambo, 1958** , **Mokbel & khafagy**, [6]. **Popper** [7] described the use of a periosteal flap used to line, rather than obliterate, the mastoid cavity. **Palva**, [8] went on to describe a modification of Popper’s flap as a musculoperiosteal flap to obliterate the mastoid bowl. **Palva, 1979** further added the use of bone chips and bone pate´ in combination with a musculoperiosteal flap. In addition to bone pate , other materials that have been described as implants for mastoid obliteration include fat grafts, cartilage,

fascia, bone chips, and ceramic materials such as hydroxyapatite [9].

The best soft tissue flap in mastoid obliteration should fulfill, Smooth surface, good vascularity, keeping volume and easy harvesting. For the obliterated cavity to re-epithelialize quickly, the surface layer of the reconstruction should provide a healthy base. the choice of soft tissue flaps is more important than that of the filler materials.

The commonest soft tissue flaps used in mastoid obliteration are random flaps, but muscle incorporated in the flap tends to lose volume with time due to atrophy. Also, the periosteal flap can retract compromising its role as the covering layer for the filler materials and the tip of the flaps may become necrotic due to unreliable vascular supply [4].

Mokbel and Khafagy, [6] advocate using three pedicled flaps to cover the bone paste for their mastoid obliteration. The best filler material in mastoid obliteration should fulfill biocompatibility, ability to maintain its volume with time, resistance to infection, and easy removal at revision surgery. The most popular filler materials are autologous bone and cartilage. Autologous bone can be in the form of bone chips or bone paste. Many surgeons use a combination of both as in most our cases. The bone chips provide the bulk, whereas bone paste creates a smooth layer over the surface of the bone chips. However, bone paste loses volume with time. Autologous cartilage, on the contrary, holds its volume well, but it is limited by the amount especially in revision surgery and can be harvested from the conchal and tragal areas. Because of the low metabolism of the cartilage, it maintains its shape and volume even if it is only covered by free fascia grafts in the mastoid bowl.

In recent years, there have been a number of alloplastic materials used for mastoid obliteration. It is important that these materials be covered by soft tissue pedicle flaps rather than free fascia grafts. The flap should be well vascularized and adequate in size to prevent exposure and leakage of the filler materials into the ear canal which occurred in one of our cases in which we used alloplastic filler. The most commonly used alloplastic fillers are probably hydroxyapatite

granules. The perceived benefits of the alloplastic materials are that they are not contaminated by the infection and 'cholesteatoma seeds' around the surgical field and they are easy to use also help in revision surgery. They usually withstand infection better than bone paste. The cost disadvantage of using these alloplastic materials can be offset by the shorter surgical time. Another commonly used alloplastic filler is Bioactive glass which is synthetic biocompatible bone substitute that contains silica. We used it (s53p4) in 2 cases it has bonebonding capacity and is antibacterial [4].

In a pilot study of using bioactive glasses S53P4 granules for mastoid obliteration on 14 patients, **Silvola**, [10] reported that all ears became dry. Two cases had leakage of the granules into the ear canal due to inadequate soft tissue cover over the granules which had occurred in one of our case. It is interesting that **Silvola**, 2012 used temporalis fascia to cover the granules in five of his cases, but we used it in all our cases.(Table1)

One noticeable finding among the reports was that residual cholesteatoma was almost exclusively found in the middle ear or the ear canal instead of the obliterated area of the mastoid cavity. **Kronenberg et al**, [11] and **Vercruyssen et al**, [12]. Monitored their patients routinely with interval non-EPI DWI MRI, whereas **Edfeldt et al**, [13] monitored the patients systematically for many years without MRI. All of them observed that residual cholesteatomas were in the tympanic cavity and that recurrent cholesteatomas were mostly related to partial absorption of the bony canal causing mini-retraction pocket to develop. we followed up our cases both clinically and radiologically using DW- MRI and the only discovered recidivistic case was 9 month post operatively and was in the middle ear cavity. However, **Kang et al**, [14] did report three cases of residual cholesteatoma within the mastoid cavity out of a total cohort of 200 cases.

CONCLUSION

Mastoid obliteration can be used in combination with either the ICW or CWD techniques. It is well tolerated and gives favourable long-term results, including in the paediatric population. It is certainly the

treatment of choice for persistent discharging mastoid cavities. The use of non-EPI DW MRI could detect cholesteatoma greater than 3mm diameter and could have the potential to replace the need for second look tympanoplasty. Whether mastoid obliteration can enhance middle ear ventilation and improve the success rate of hearing restoration remains uncertain, and would need further research

REFERENCES

- 1-**Hideaki Suzuki, MD, PhD1***, **Shoji Ikezaki, MD1***, **Kei Imazato, MD, Hiroki Koizumi, MD1, Toyoaki Ohbuchi, MD, PhD1, Nobusuke Hohchi, MD1, and Koichi Hashida, MD1**, Partial Mastoid Obliteration Combined With Soft-wall Reconstruction for Middle Ear Cholesteatoma *Annals of Otolaryngology, Rhinology & Laryngology* 2014 ;123(8):571–575.
- 2-**George Kurien1, Kate Greeff2, Nahla Goma1 and Allan Ho1.:** Mastoidectomy and mastoid obliteration with autologous bone graft: a quality of life study *Journal of Otolaryngology - Head and Neck Surgery* 2013; 42:49.
- 3-**Samad Ghiasi;** Mastoid Cavity Obliteration with Combined Palva Flap and Bone pâté *Iranian Journal of Otorhinolaryngology* 2015; 27(1).
- 4-**Yung, M. & Bennett, A.** Use of mastoid obliteration techniques in cholesteatoma. *Current opinion in otolaryngology & head and neck surgery* 2013;21; 455-460.
- 5-**Kisch J.** Temporal muscle grafts in the radical mastoid operation. *J laryngol.* 1928; 43:735.
- 6-**Mokbel, K. M. & Khafagy, Y. W.** Single flap with three pedicles, bone pâté and split-thickness skin graft for immediate mastoid obliteration after canal wall down mastoidectomy. *European Archives of Oto-Rhino-Laryngology* 2012;269: 2037-2041
- 7- **Popper O,** periosteal flap grafts in mastoid obliteration *S Afr Med J* 1935; 17:77-8.
- 8-**Palva T.** surgery of chronic ears without cavity. *Arch otolaryngol.*1963;570-80.
- 9- **Edfeldt, L., Strömbäck, K., Danckwardt-Lillieström, N., Rask-Andersen, H., Abdsaleh, S. & Wikström, J.** Non-echo planar diffusion-weighted MRI increases follow-up accuracy after one-step step 10-SILVOLA, J. T. 2012. Mastoidectomy cavity obliteration with bioactive glass: a pilot study. *Otolaryngology--Head and Neck Surgery*, 2013;147: 119-126.
- 11-**Kronenberg, J., Shapira, Y. & Migirov, L.** Mastoidectomy reconstruction of the posterior wall and obliteration (MAPRO): Preliminary results. *Acta Oto-Laryngologica*, 2012;132: 400-403
- 12-**Vercruysse J, De Foer B, Somers T.** Long-term follow up after bony mastoid and epitympanic obliteration: radiological findings. *J Laryngol Otol* 2010; 124:37–43.
- 13-**Edfeldt L., Strömbäck, K., Kinnefors, A. & Rask-Andersen, H.** Surgical treatment of adult cholesteatoma: long-term follow-up using total reconstruction procedure without staging. *Acta otolaryngologica* 2012.133: 28-34.
- 14-**Kang M.-K., Ahn, J.-K., GU, T.-W. & Han, C.-S.** Epitympanoplasty with mastoid obliteration technique: a long-term study of results. *Otolaryngology Head and Neck Surgery* 2009;140: 687-691.

To Cite This Article: Alsayed AA, Mobashir MK, abouelezz S, alhady A

. MASTOID OBLITERATION IN CHOLESTEATOMA SURGERY, DIFFERENT MATERIALS . *Zumj* 2020; 26(4): doi: 10.21608/zumj.2019.13572.1256.

abdulmageed, A., Mobasher, M., abouelezz, S., elhady, A. MASTOID OBLITERATION IN CHOLESTEATOMA SURGERY, DIFFERENT MATERIALS. *Zagazig University Medical Journal*, 2019 July. 2020 Volume 26 Issue 4; (604-611): -. doi: 10.21608/zumj.2019.13572.1256