

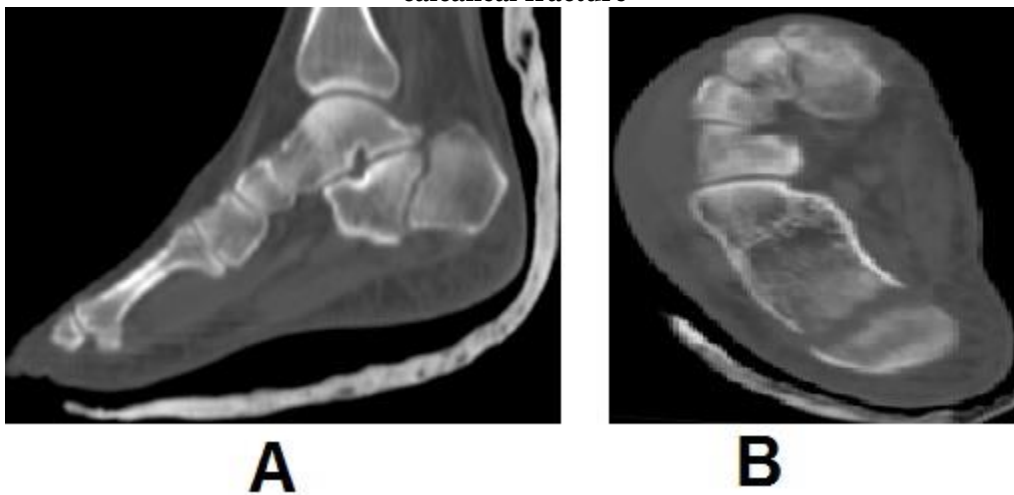
Figure (4):

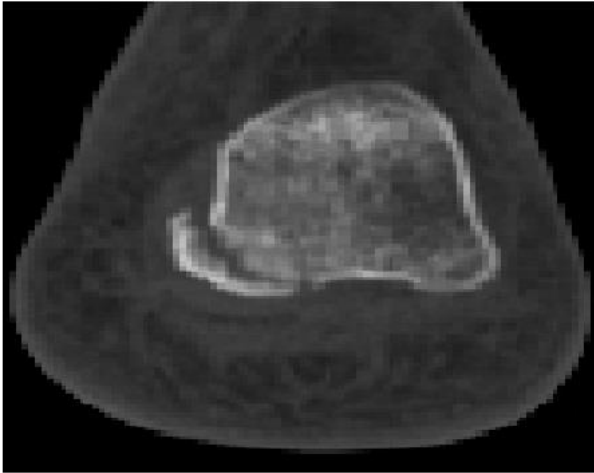
Two different traumatic cases with MDCT sagittal MPR image showed fracture of anterior calcaneal process (encircled in black) represented **extra-calcaneal fracture (Type A)**.

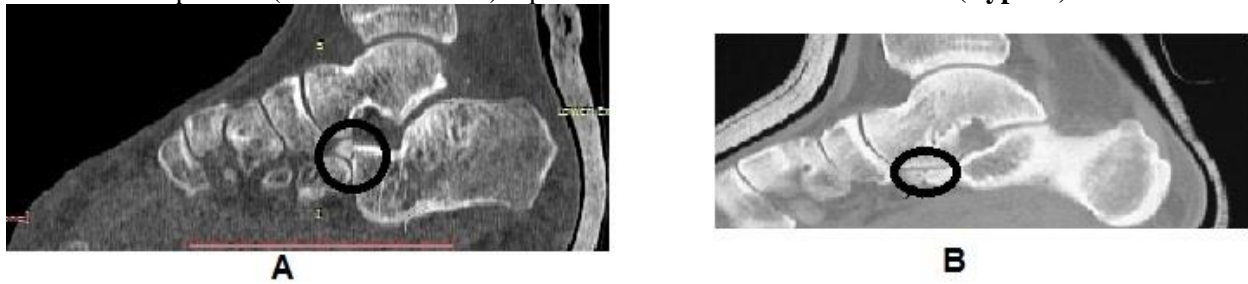

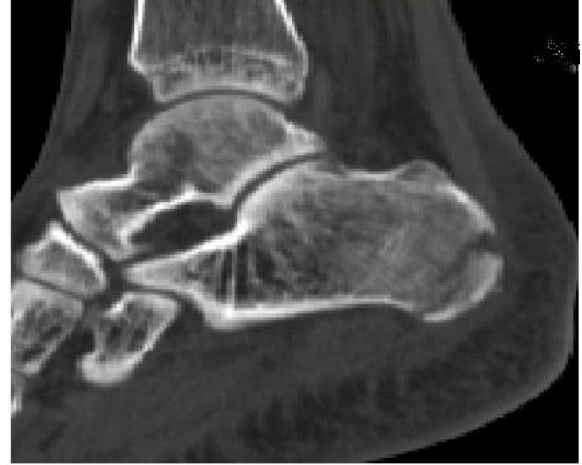Figure (5):

Two different traumatic cases, (A) MDCT sagittal MPR image showed fracture of mid calcaneal body and (B) MDCT axial image showed calcaneal body fracture. Both cases diagnosed as **Type B extra-calcaneal fracture**

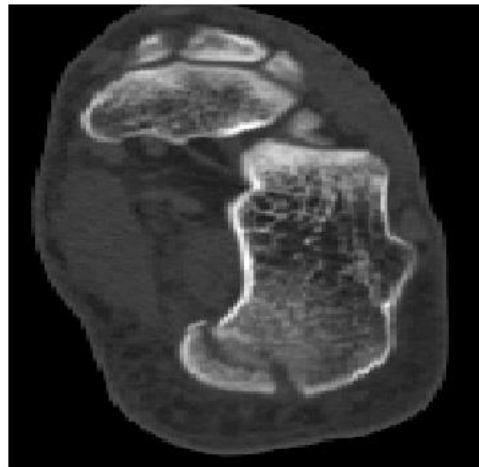




A



B



C

Figure (6):

Traumatic case showed **posterior calcaneal tuberosity fracture (Type C)** in MDCT coronal MPR image (A), sagittal MPR image (B) and axial image.