

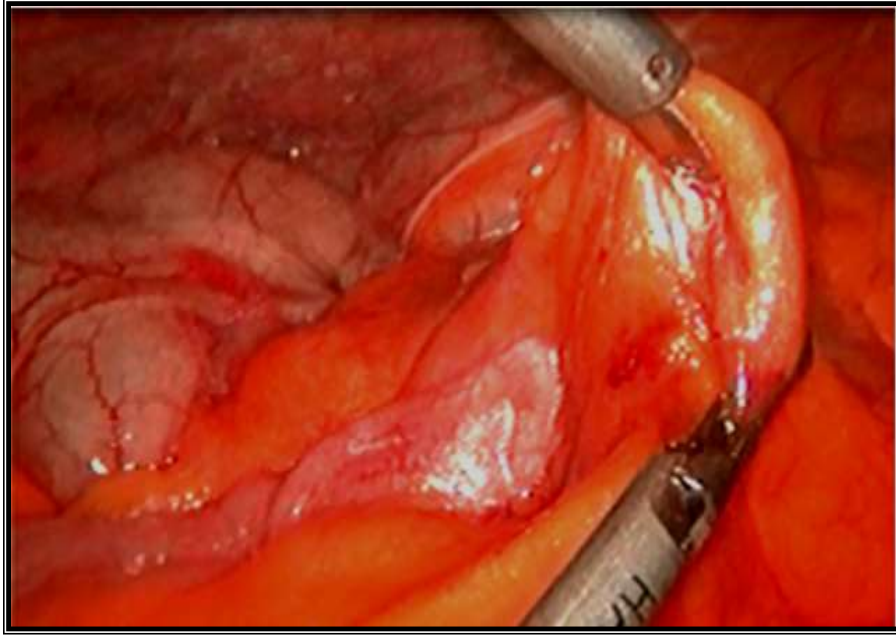Fig. (1S) Medial approach dissection in. Laparoscopic Rt. Colectomy

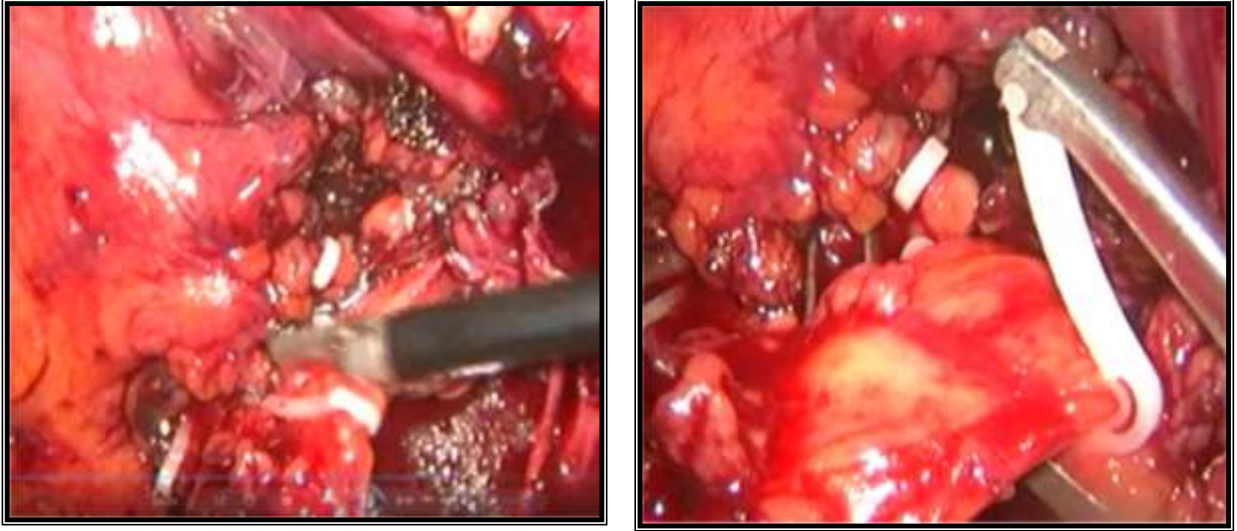


Fig. (2S): Dissection & Ligation of right colic vessels.

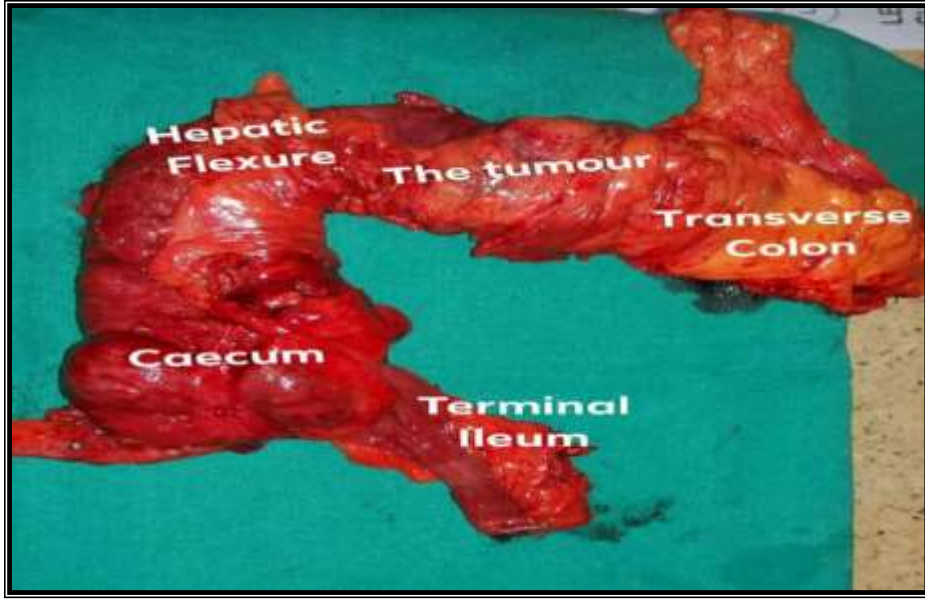


Fig. (3S) Specimen for resected transverse colonic carcinoma